PHILOSOPHY SERIES / TRAUMA & ORTHOPAEDICS

Philosophy of Inter- and Subtrochanteric Fractures

Understanding and Treatment



NINE CHAPTERS | MODESTY-ADAPTED ILLUSTRATED EDITION

Mr Peyman Bakhshayesh

MD, PhD, MBA

Consultant Trauma and Orthopaedic Surgeon

19 October 2026

peymanorthopaedics.world

Contents and approach

Chapter	Subject	Page
1	Introduction and the author's clinical philosophy	3
2	Epidemiology and the burden of injury	6
3	Classification and treatment planning	10
4	Traction table versus lateral positioning	17
5	Reduction and fixation technique	25
6	Positive medial calcar support versus anatomical reduction	31
7	Follow-up: healing the person and the fracture	36
8	Failure: patterns and assessment	39
9	Outcomes and reconstruction after failure	42
	References and illustration credits	45

How to read this book

This book joins the author's operative philosophy to referenced evidence. First-person passages express experience and preference. Study results retain their own populations, denominators and limitations. Lateral positioning, cortical support and valgus are considered as separate decisions rather than a proven combined treatment effect.

The aim is dependable fixation that supports early rehabilitation. Stable anatomical reduction remains appropriate; deliberate excessive valgus is not advocated. Restrictions on loading, when needed, require an individual reason and review plan.

The cover and lateral-positioning plates use a lightly illustrated adaptation of the author's clinical photograph. An opaque blue modesty drape covers the pelvis and groin. The photographed side-lying setup guides this teaching adaptation; it is not an unaltered clinical photograph. Original radiographs and fluoroscopy retain their existing anonymous crops.

Positioning and imaging plates

Lateral-positioning illustrations: pages 19 and 21 (the same view). Supine/lateral comparison: page 22. Fracture and entry imaging: pages 23-24. Clamp-assisted reduction: page 28. Completion views of the hip, shaft and distal fixation: pages 29-30.

Chapter 1 Introduction

The challenge in modern trauma care

Intertrochanteric and subtrochanteric fractures present a continuing challenge to modern healthcare in the United Kingdom and elsewhere. They combine an urgent loss of mobility with a fracture whose behaviour depends on its geometry, cortical support and surrounding muscle attachments. Many patients are older and frail; others sustain substantial injuries at a younger age. The same anatomical region therefore contains very different clinical problems.

In this book, I bring together my years of experience in treating these fractures and the reasoning that guides my decisions. I want the reader to understand why the fragments have displaced, what will resist reduction, where stability has been lost and what the chosen fixation must achieve. The radiograph is the beginning of that discussion. The patient's health, body shape, previous mobility and expectations complete it.

The workload is substantial, and an ageing population continues to influence the demand on trauma services. However, an increase in the number of fractures does not automatically demonstrate an increase in the proportion of complex patterns. My observation that difficult combinations of fracture morphology and patient factors are frequently encountered should be understood as clinical experience, rather than as a measured national trend. Chapter 2 separates these questions. [1–3]

The purpose of classification

Several classification systems have shaped our understanding, including AO/OTA, Evans and its Jensen modification, Boyd–Griffin, Seinsheimer and Russell–Taylor. Each draws attention to a different feature: the direction of the fracture line, fragmentation, the medial buttress, the lateral wall or the proximal extension of a subtrochanteric injury. Their categories are not interchangeable.

My approach is to use classification as a language for thinking and communicating. When I describe a fracture, I also want to explain what the code means mechanically. A useful description tells the team whether cortical contact can be restored, whether controlled impaction is possible and whether there is a risk of shaft medialisation, varus, rotational error or excessive shortening.

Treatment begins with the person

Chronological age is one part of the assessment. Physiological reserve, cognition, cardiopulmonary disease, anticoagulant use, bone quality and previous independence can be more important to the immediate plan. Body habitus affects positioning, access and imaging; femoral geometry can affect the suitability of an implant. These factors should be anticipated before entering theatre.

The practical aim is a reduction and fixation construct that supports recovery. For the usual older hip fracture patient, NICE recommends operating with the aim of permitting immediate unrestricted weight bearing. The chosen operation and the postoperative instructions must work together towards that aim. [4]

Understanding the deformity

Muscle attachments explain displacement

When the subtrochanteric fracture leaves the trochanters attached to the proximal fragment, that fragment commonly lies abducted, flexed and externally rotated. The shaft is drawn into adduction and may shorten. The precise deformity changes when a trochanter or its tendon attachment becomes a separate fragment. The same muscle therefore has different consequences in different fracture configurations. [7,17]

The supplied illustration on the following page should be read with this qualification. It shows selected attachments and typical directions of pull. It does not imply that every intertrochanteric fracture has the same fragment pattern or that every muscle remains attached to the head–neck fragment.

Attachment	Expected mechanical contribution
Gluteus medius and minimus	Abduct the fragment retaining the greater trochanter.
Iliopsoas	Flexes the fragment retaining the lesser trochanter; may displace a separate lesser-trochanter fragment.
Short external rotators	Contribute to external rotation when their attachments remain on the proximal fragment.
Adductors	Pull the shaft medially; contribute to adduction and shortening within the overall muscle envelope.
Gluteus maximus	Acts through the gluteal tuberosity and iliotibial tract; its effect depends on the retained attachments and fracture level.

Reduction must address more than length

Traction may improve shortening while leaving flexion, varus or rotational displacement unresolved. In a subtrochanteric injury, bringing the shaft towards the displaced proximal segment can be more useful than increasing traction against an uncorrected deformity. Assessment in both anteroposterior and lateral projections is essential. [17]

My philosophy is to identify the missing mechanical support before selecting the means of fixation. I ask whether the medial cortex can transmit load, whether the lateral wall can contain controlled collapse and whether the fracture extends into the entry region or farther down the shaft. These questions link the muscle diagram to the classification chapter.

The first planning questions

Before deciding on an implant, establish the fracture’s full extent, its reducibility, the quality of the available bone and the patient’s realistic mobilisation needs. Adequate imaging and an explicit reduction strategy help the team prepare appropriate equipment and anticipate when additional reduction tools may be required.

Anatomical teaching plate

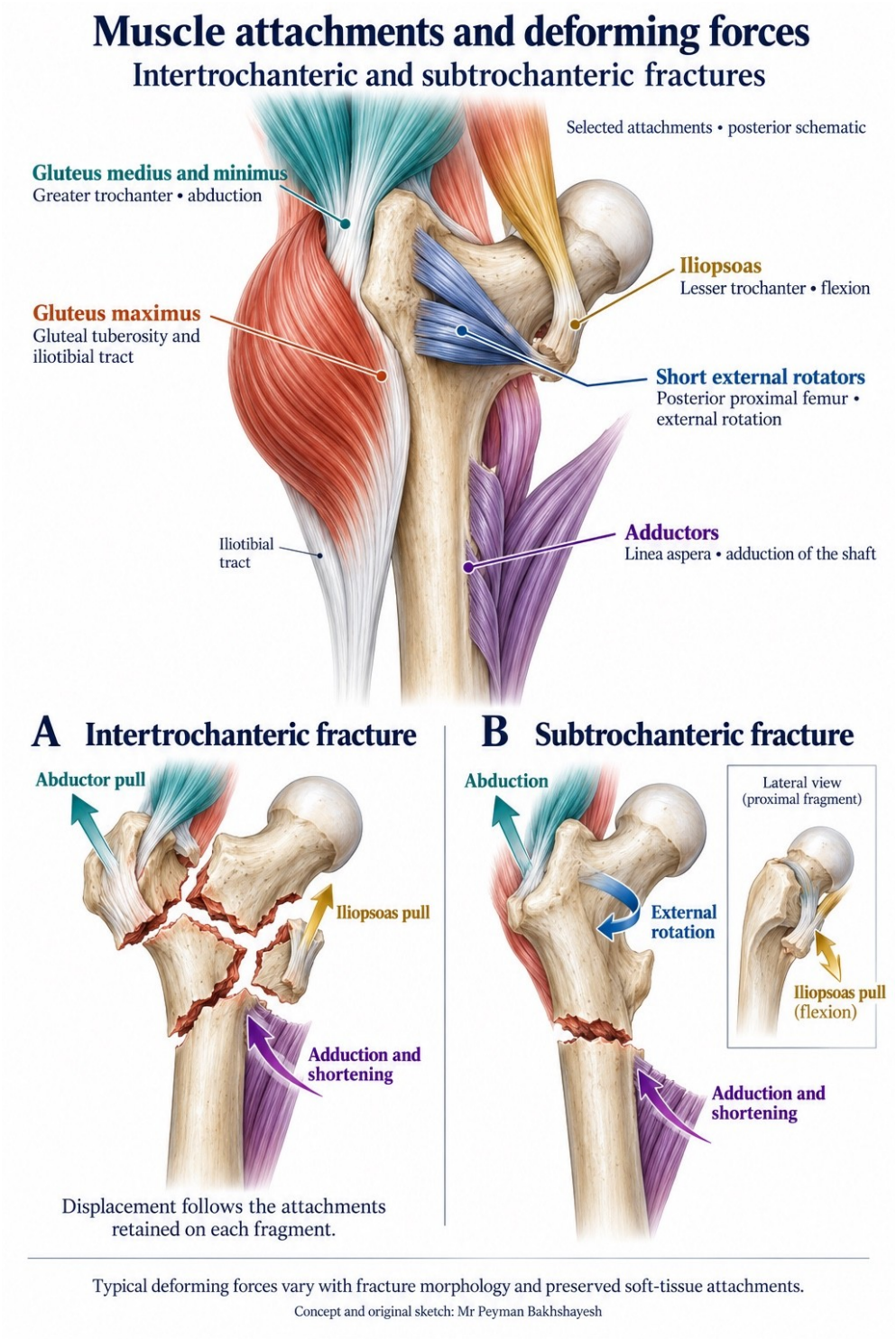

Figure 1.1. Muscle attachments and typical deforming forces. Author-supplied illustration based on Mr Peyman Bakhshayesh's original sketch. The effect of each muscle depends on its retained fragment attachment.

Chapter 2 Epidemiology

The national burden of hip fracture

The NHFD 2025 report provides the following comparison for England, Wales and Northern Ireland. It records all hip fractures, rather than intertrochanteric and subtrochanteric fractures alone. [1]

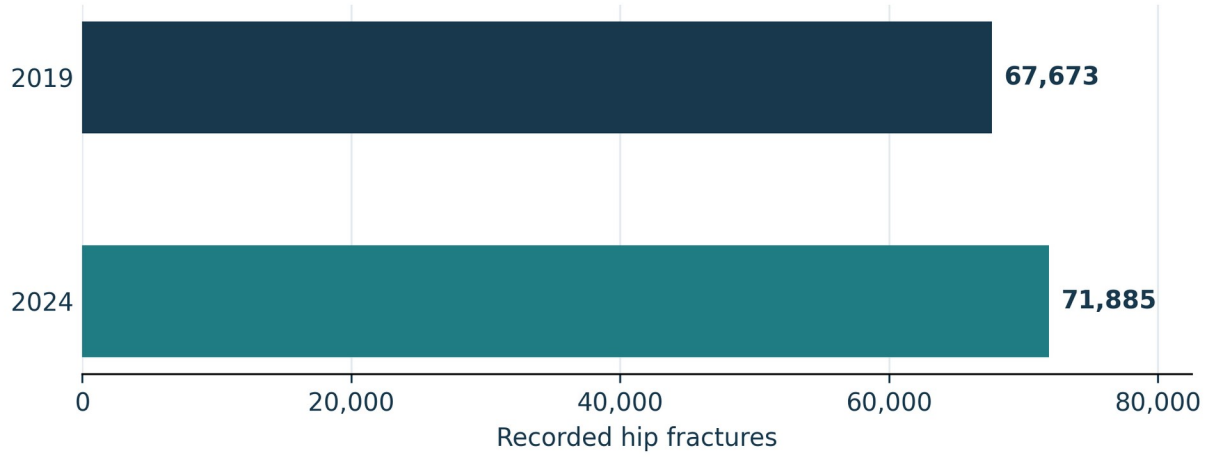

Figure 2.1. Recorded hip fractures in 2019 and 2024. Source: NHFD 2025 report, page 3. Bars begin at zero. [1]

Measure	Reported value
Increase in recorded hip fractures	4,212 fractures; 6.2% between 2019 and 2024
Growth in the population aged over 80	13.4% over the same interval
Surgery by the day after presentation	58% in 2024; 68% in 2019

What an increasing count means

A service may treat more fractures even when the risk within a particular age group is falling. The number of older people, their age distribution and the rate of fracture within each age group all contribute to the workload. A national count is therefore different from an age-standardised incidence rate.

For planning theatre capacity, ward beds and rehabilitation, the absolute number matters. For assessing whether prevention is working, rates adjusted for population size and age are more informative. Neither measure, on its own, establishes that unstable fracture morphology has become more common.

Geographical boundaries matter

NHFD data from England, Wales and Northern Ireland should not be presented as a complete count for the United Kingdom. Scotland has a separate audit programme. Likewise, a denominator containing femoral neck fractures should not be used to interpret a percentage calculated only among extracapsular fractures.

Age and sex in the hip fracture population

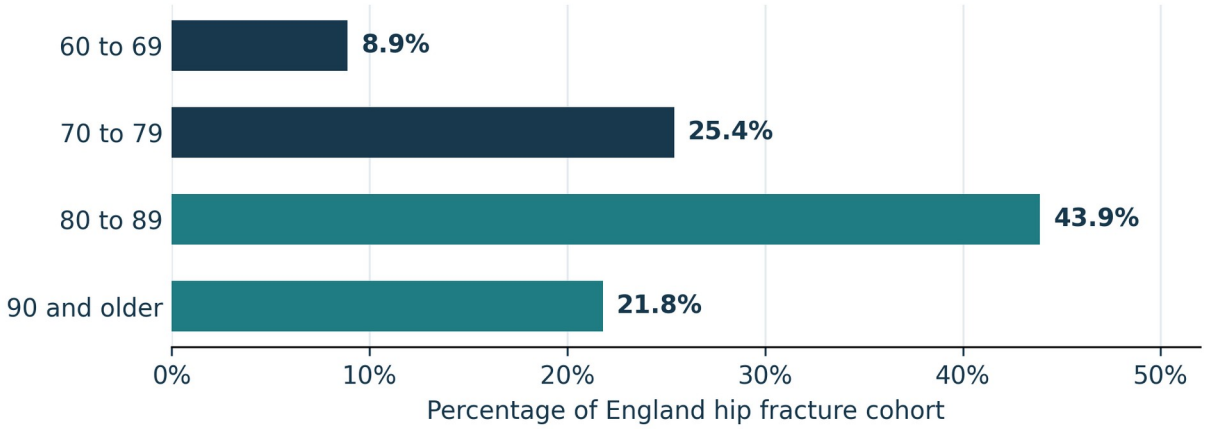

Figure 2.2. Age distribution in the England cohort in 2024, n = 65,133. Source: NHFD 2025 report, page 3. [1]

Population	Recorded patients	Women	Mean age
England	65,133	69.0%	82.4 years
Wales	4,401	68.3%	81.9 years
Northern Ireland	2,347	69.7%	80.7 years

Table 2.1. NHFD demographic table for 2024. Its reported country totals differ slightly from the headline total; they are retained without adjustment. These are all-hip-fracture cohorts. [1]

Implications for assessment

The clinical consequence of this age profile is the need to assess the fracture alongside frailty, cognition, nutrition, previous mobility and the home situation. Rehabilitation capacity and support after discharge affect what can be achieved with technically successful fixation.

Sex distribution describes who sustains the injury; it does not determine an individual’s operative treatment. Similarly, advanced age should not be used as a substitute for an assessment of physiological reserve or for discussion of the patient’s wishes.

Fracture risk and complexity are different outcomes

Osteoporosis, falls and ageing help explain the fragility-fracture burden. They do not create a simple one-to-one relationship with the number of fragments on the radiograph. A low-energy fall can produce an unstable pattern, while a more substantial mechanism can sometimes produce a relatively simple fracture line.

Body mass index and body shape should also be interpreted carefully. They can change surgical access, positioning and mechanical demands, but a rise in obesity cannot be used without population evidence to explain an increase in intertrochanteric fracture incidence. Local observations should be tested against data collected with consistent definitions.

Evidence specific to extracapsular fractures

Mattisson and colleagues studied adults undergoing primary surgery for non-pathological trochanteric or subtrochanteric fractures in the Swedish Fracture Register during 2014–2016. [2]



Figure 2.3. Fracture location by ICD-10 coding in the Swedish surgical cohort. Percentages calculated from published counts; n = 10,548. [2]

Characteristic or outcome	Numerator and denominator	Value
Mean age	10,548 patients	82.4 years
Women	7,317 / 10,548	69.4%
Fall at the same level	8,796 / 10,548	83.4%
Injury at residence or accommodation	7,631 / 10,249	74.5%
Death within 30 days	811 / 10,548	7.7%
Death within one year	2,731 / 10,548	25.9%

Table 2.2. Descriptive cohort data and all-cause mortality. Percentages are recalculated to one decimal place from the published counts. [2]

Interpreting this cohort

The subtrochanteric percentage applies to surgically treated extracapsular injuries, not all hip fractures. Pathological and nonoperatively managed fractures were excluded; register coverage was incomplete. Historical AO grouping in this study combined reverse-oblique and subtrochanteric injuries, so it should not be treated as a direct map of current AO codes. [2]

What these observations change

For clinical planning, the combination of fragility injury and a substantial mortality burden makes the perioperative pathway part of treatment. The operation must be accompanied by medical assessment, adequate analgesia, prevention of avoidable delay and an early plan for mobilisation. An association between delay and mortality in observational data does not establish that delay alone caused the deaths.

International trends and distinct patient groups

International comparisons

Sing and colleagues analysed 4,115,046 hip fractures in 20 healthcare databases from 19 countries and regions, covering patients aged at least 50 during 2005–2018. Their reported age- and sex-standardised incidence rates ranged from 95.1 per 100,000 in Brazil to 315.9 in Denmark. These are study-period estimates for all hip fractures, not 2026 rates for intertrochanteric fractures. [3]

Although incidence declined in most participating populations, their projected annual fracture count nearly doubled between 2018 and 2050. This is a demographic projection, not an observed outcome or a universal forecast for every country. The study illustrates how falling individual risk can coexist with rising service demand. [3]

Subtrochanteric injury includes several populations

Population	Clinical and epidemiological distinction
Older adults with fragility fractures	Often a low-energy mechanism; assess falls, bone health, frailty and previous function.
Younger adults after major trauma	Mechanism, associated injuries and soft-tissue damage may dominate early management.
Atypical femoral fractures	Defined by a specific radiographic pattern; not synonymous with all subtrochanteric fractures.
Pathological or periprosthetic fractures	Require separate diagnostic and classification pathways; do not pool automatically with ordinary native-bone traumatic fractures.

Atypical femoral fractures may occur with or without antiresorptive exposure. The 2014 ASBMR task-force report cited absolute rates of approximately 3.2–50 per 100,000 person-years among bisphosphonate users, with higher rates after longer exposure. These historical estimates are specific to atypical fractures in exposed populations; they are not the incidence of all subtrochanteric injuries. The benefits of osteoporosis treatment must be considered alongside this uncommon adverse event. [16]

Measuring the author’s clinical observation

An audit intended to establish whether complex patterns are increasing should record a stable catchment population, consistent age bands and classification versions, the mechanism, pathological or atypical features and whether fractures cross anatomical regions. A rise in referrals to a specialist trauma unit may reflect referral practice as well as a change in underlying incidence.

The practical implication for my philosophy is that a population label cannot replace individual fracture analysis. Epidemiology tells us whom to prepare for and how much capacity may be needed. Morphology and patient assessment determine the treatment plan for the person in front of us.

Chapter 3 Classification

Classification should reveal the mechanical problem

A useful classification describes the injury consistently and directs attention to features that may change reduction or fixation. In these fractures, I first identify the anatomical region, then examine the medial support, lateral wall, fracture-line direction and distal extension. A named category should be accompanied by a short description of those findings.

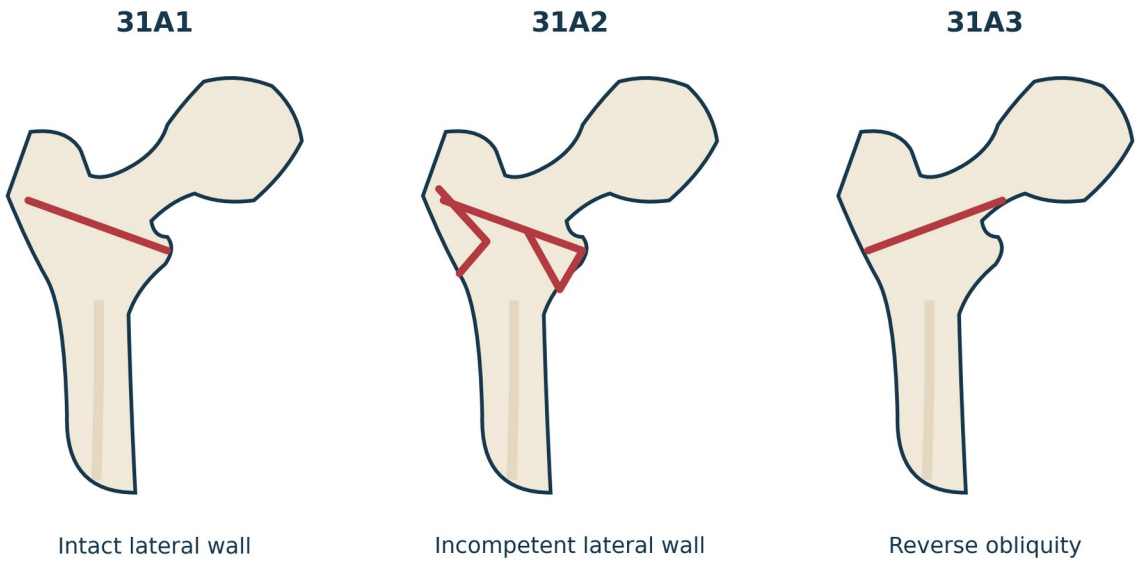

Figure 3.1. Original simplified schematics of the main AO trochanteric groups. They show selected fracture features and are not exhaustive templates. [5–7]

Group	Current AO description	Feature to examine
31A1	Pertrochanteric pattern with an intact lateral wall	Preserved or recoverable support after reduction; a small posteromedial fragment may still be present.
31A2	Multifragmentary pertrochanteric fracture with an incompetent lateral wall	Coronal fragmentation, lateral-wall competence and the extent of the posteromedial defect.
31A3	Intertrochanteric fracture, commonly termed reverse oblique	A fracture line crossing both cortices in a mechanically different orientation; assess extension.

Table 3.1. Main groups used in the current AO Surgery Reference. State the version or reference used when comparing older studies. [5–7,15]

A fracture centred below the lesser trochanter should be described as subtrochanteric and coded according to its actual location and morphology. Do not automatically apply 31A3 to every subtrochanteric fracture. A combined trochanteric–subtrochanteric pattern needs its extension stated explicitly.

The AO 31A3 subgroups

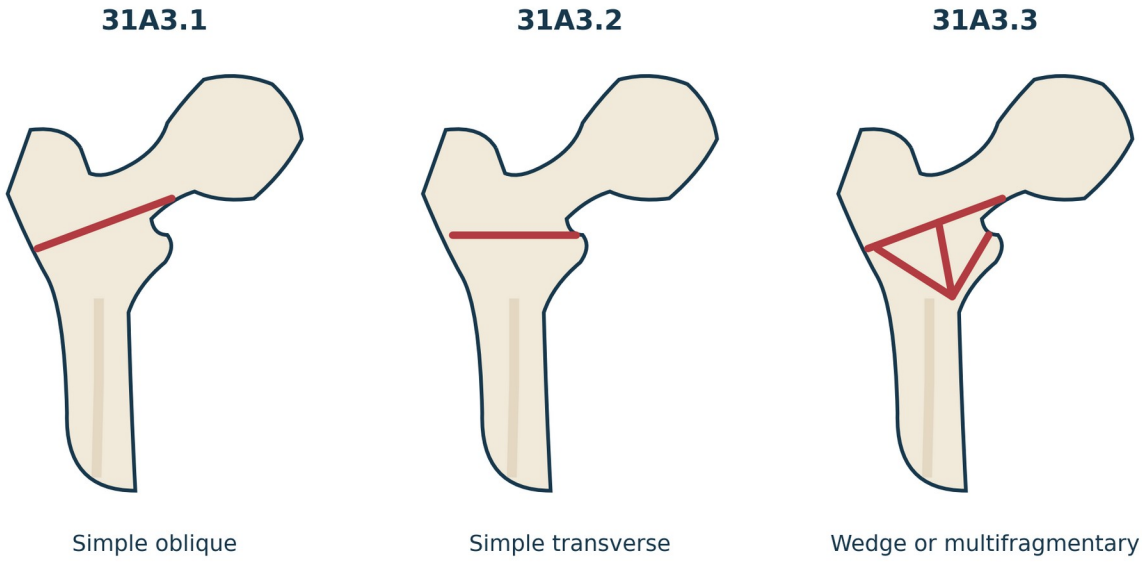

Figure 3.2. Original schematics of the AO 31A3 subgroups. The orientation in 31A3.1 is reverse oblique. Red lines indicate fractures; no displacement is simulated. [7]

Code	Description
31A3.1	Simple oblique fracture
31A3.2	Simple transverse fracture
31A3.3	Wedge or multifragmentary fracture

Why the direction matters

In a conventional pertrochanteric pattern, controlled sliding can produce impaction when the remaining walls provide containment. With reverse obliquity, the fracture geometry provides less resistance to medial translation of the shaft. The direction of collapse can therefore increase displacement rather than create a stable contact surface. [7]

Simple in the AO description means that there are two main fracture components; it does not mean mechanically stable, easy to reduce or suitable for a DHS. This distinction is particularly important for 31A3.1 and 31A3.2.

What to record in addition to the code

Record whether the fracture extends below the lesser trochanter, whether there is an additional coronal or anterior fragment and whether a proximal fissure reaches the anticipated nail entry region. A single anteroposterior image can understate the fracture’s three-dimensional complexity.

My treatment planning therefore includes a description of the intended reduction and the residual support. Implant choice follows that analysis. Detailed nailing technique and the management of specific variants belong in the operative chapters; an A3 code alone cannot provide that plan.

Evans and the Jensen modification

The original Evans system

Evans' 1949 classification emphasised whether a stable reduction could be obtained. Its type I covered the usual oblique trochanteric pattern, subdivided according to displacement, reducibility and the condition of the medial cortical support. Type II described reverse obliquity. Those original labels should be distinguished from the later five-type system commonly called Evans–Jensen. [8,9]

The commonly used five-type modification

Jensen type	Morphology	Usual mechanical interpretation
I	Two-part fracture without displacement	Potentially stable with support preserved.
II	Two-part fracture with displacement	Potentially stable after satisfactory reduction.
III	Three-part fracture with a separate greater-trochanter fragment	Loss of posterolateral support.
IV	Three-part fracture with a separate lesser-trochanter or posteromedial fragment	Loss of posteromedial support.
V	Four-part fracture with both trochanteric fragments	Loss of both posteromedial and posterolateral support.

Table 3.2. Jensen modification of Evans, commonly numbered I–V. Some teaching sources instead use IA, IB, IIA, IIB and III; specify which notation is being used. [9]

Clarifying the small lesser trochanter fragment

My practical point is that a small lesser-trochanter fragment does not necessarily destroy the remaining load-bearing buttress. This observation helps assess stability, but it is not the formal definition of Jensen type II, which describes a displaced two-part fracture.

Similarly, loss of the medial calcar is not the definition of Jensen type III. In the usual five-type numbering, type III concerns the greater trochanter and posterolateral support; type IV concerns the lesser trochanter and posteromedial support. Keeping the morphology beside the number avoids a potentially important communication error.

Stability is assessed after reduction

The difference between a reducible displaced fracture and one with a substantial cortical defect is central to the Evans concept. For modern planning, medial contact, the lateral wall and the direction of the fracture line should all be examined. A fragment count cannot replace that assessment.

The medial buttress and the lateral wall

The size of the lesser trochanter fragment is not enough

A small avulsion fragment may leave a broad area of cortical contact available. A larger posteromedial fragment may remove a substantial load-bearing surface. Its distal extent and the remaining cortical apposition are therefore more informative than the presence of a separate lesser trochanter alone.

This is consistent with the current AO category 31A1.3, which allows posteromedial involvement while the lateral wall remains intact. It supports the principle behind my description of a potentially stable fracture with a small lesser-trochanter fragment. It should not be used to imply that all three-part fractures are stable. [5]

Lateral wall assessment

Hsu and colleagues identified 20.5 mm as a threshold associated with secondary lateral-wall fracture after DHS fixation. Current AO descriptions use this measurement in distinguishing competent from incompetent lateral walls. It is a classification and risk-assessment aid, rather than a stand-alone indication for every patient. [5,6,13]

The measurement is taken on the anteroposterior view from a point 3 cm below the innominate tubercle, following the standard 135-degree measurement line proximally until it intersects the fracture line. Rotation and projection influence the measurement; a satisfactory reduced or traction view is preferable. [5,6]

Finding	What it means for planning
Recoverable medial contact and competent lateral wall	Controlled impaction may be feasible after reduction.
Substantial posteromedial defect	Anticipate greater dependence on the fixation construct and avoid accepting varus.
Incompetent lateral wall	Consider the risk of loss of containment and excessive collapse.
Reverse obliquity or subtrochanteric extension	Assess shaft translation, the full distal extent and an appropriate intramedullary strategy.

Where a DHS fits in the philosophy

A DHS remains appropriate for many reducible conventional trochanteric patterns with adequate support. NICE recommends a sliding hip screw in preference to an intramedullary nail for trochanteric fractures above and including the lesser trochanter, except reverse-oblique fractures. NICE recommends an intramedullary nail for subtrochanteric fractures. These recommendations should be applied with attention to the actual pattern and reduction. [4]

Seinsheimer classification

Seinsheimer’s system describes subtrochanteric fractures by displacement, the number of principal fragments and the configuration of the fracture lines. The location of the lesser trochanter helps identify which segment retains the iliopsoas attachment. [11]

Type	Description
I	Undisplaced fracture or displacement less than 2 mm.
IIA	Two-part transverse fracture.
IIB	Two-part spiral fracture with the lesser trochanter attached to the proximal fragment.
IIC	Two-part spiral fracture with the lesser trochanter attached to the distal fragment.
IIIA	Three-part spiral fracture; the third fragment contains the lesser trochanter and an inferior cortical spike.
IIIB	Three-part spiral fracture with a separate butterfly fragment.
IV	Comminuted fracture with four or more principal fragments.
V	Subtrochanteric fracture extending through the greater trochanter into the trochanteric region.

Table 3.3. The Seinsheimer categories and subcategories. Small fissures should not be counted indiscriminately as major fragments. [11]

How I use this description

The classification encourages a useful question: which cortical fragment is missing from the load path? A long posteromedial fragment can leave a substantial defect even when the total fragment count is modest. Conversely, a complex appearance does not tell the surgeon whether useful cortical contact can be restored without unnecessary soft-tissue stripping.

For each pattern, I add the length and direction of the main fracture line, the amount of comminution, any proximal extension and the quality of the remaining bone. The classification then supports a reduction strategy rather than becoming a substitute for one.

Limits of prediction

Seinsheimer’s original work arose in a different implant era. Historical failure rates should not be presented as current probabilities with modern cephalomedullary fixation. Reproducibility studies have also found limited agreement for subtrochanteric classification systems. A clear morphological description is therefore valuable when colleagues disagree about a numerical category. [11,14]

Russell Taylor classification

Russell–Taylor describes subtrochanteric fractures using two anatomical questions: does the fracture extend into the piriformis fossa, and is the lesser-trochanter or posteromedial cortical region compromised? The resulting matrix is useful for understanding the original system. [12]

Proximal extension	A Medial support preserved	B Lesser trochanter or medial support involved
I Piriformis fossa intact	IA	IB
II Fracture extends into piriformis fossa	IIA	IIB

Table 3.4. Russell–Taylor matrix. The A/B distinction concerns the integrity of the lesser-trochanter and posteromedial support region. [12]

The meaning of IIB

Russell–Taylor IIB combines extension into the piriformis fossa with disruption or comminution involving the lesser trochanter and medial support. The medial defect is only one part of its definition. A fracture cannot be called IIB on the basis of calcar loss alone.

This is why an unstable Evans or Jensen fracture is not directly equivalent to Russell–Taylor IIB. The systems ask different questions and apply to overlapping, but different, fracture configurations. If both descriptions are used, record the actual morphology supporting each.

Historical purpose and modern relevance

The system was developed when the integrity of the piriformis entry region strongly influenced whether an intramedullary device could be used. Contemporary greater-trochanter-entry cephalomedullary nails have reduced the force of that historical treatment division. Proximal extension still matters, but type II is not a modern automatic prohibition on nailing. [12]

In my planning, the classification draws attention to the proximal fragment available for control, the proposed entry point and the medial defect. I then add information about reduction, femoral geometry and distal extension. The implant must suit the whole fracture, rather than only the entry region.

Avoiding a common language error

When discussing a fracture in theatre, say “subtrochanteric fracture with a separate lesser-trochanter fragment and extension into the piriformis fossa” before relying on “IIB”. The explicit description makes the clinical problem understandable even to a team member who uses another classification.

Boyd Griffin and an integrated description

The historical Boyd Griffin categories

Type	Pattern described
I	A relatively simple fracture along the intertrochanteric line.
II	A trochanteric fracture with comminution and additional cortical fragmentation.
III	A fracture at or below the lesser trochanter with a subtrochanteric component and variable comminution.
IV	A complex trochanteric fracture extending into the proximal shaft, with fracture lines in at least two planes.

Table 3.5. Boyd–Griffin provides a historical description of increasing complexity and extension. It is not a direct conversion table for current AO groups. [10]

A classification record that guides the operation

For a practical preoperative record, I combine the named category with a description of the features that influence the operation. This retains a common language while making the surgical reasoning visible.

Field	What should be stated
Region and full extent	Trochanteric, reverse-oblique, subtrochanteric or combined; document distal and proximal extension.
Morphology	Main fracture-line direction, principal fragments and coronal-plane components.
Support	Medial cortical contact, posteromedial defect and lateral-wall competence.
Patient	Physiological reserve, previous mobility, cognition, bone quality and relevant body habitus.
Plan	Reduction method, suitable fixation options, anticipated difficulties and postoperative weight-bearing aim.

An example of a useful description

“A reverse-oblique 31A3.1 fracture with distal extension into the subtrochanteric region, medial displacement of the shaft and no satisfactory cortical contact on the presenting images. The plan must restore alignment in both projections and provide fixation appropriate to the full fracture length.”

This is an illustrative teaching example, not a record of an actual patient. It communicates more than the code alone because it explains the deformity and identifies what the treatment must correct.

My philosophy is to connect the person, the pattern and the mechanics of recovery. Epidemiology explains the scale of the problem. Classification describes the injury. Thoughtful reduction, appropriate fixation and coordinated rehabilitation turn those descriptions into treatment.

Chapter 4. Traction table versus lateral positioning

Position is part of the reduction strategy

The first question is not simply which operating table is available. It is how the fracture will behave while it is reduced, reamed and nailed. Positioning influences access to the greater trochanter, the direction in which the shaft can be manipulated, the tension of the soft tissues, fluoroscopic imaging and the ease of conversion to limited open reduction.

My preference for highly unstable intertrochanteric fractures and selected subtrochanteric fractures is lateral positioning on a radiolucent table, without sustained traction from a fracture table. This preference arises from operative experience: I find that the entry point is more accessible and that direct reduction is more comfortable when closed manoeuvres do not produce a dependable relationship between the proximal fragment and the shaft. It is a preferred method within my practice, rather than a claim that every fracture requires lateral positioning. [18]

The operative team should be competent in both approaches. A technically familiar supine technique, performed with good reduction and reliable imaging, is preferable to an unfamiliar lateral technique in which rotation, length or the sagittal view cannot be controlled.

Why the traction table remains useful

Supine positioning on a fracture table is the established arrangement for much proximal femoral fracture surgery. Traction and controlled rotation assist restoration of length and alignment, while the table maintains the limb position. The familiar arrangement is useful for trainees, radiographers and theatre staff; it can reduce the number of assistants required to maintain longitudinal alignment.

AO guidance describes good access to AP, axial and cross-table lateral images. It also emphasises adequate padding of the perineal post, protection of the genitalia, safe support of the opposite limb and appropriate torso adjustment. A successful setup includes imaging, pressure protection and anaesthetic access, rather than traction alone. [19]

Traction is a tool with a limit. When a fracture is locked, comminuted or displaced in several planes, more traction does not necessarily correct its deformity. Excessive traction can rotate the pelvis around the perineal post and interfere with access to the proximal entry point. Correcting the pelvic position and changing the reduction manoeuvre may be more useful than increasing force. [20]

Gravity, muscles and the difficult reduction

In my experience, an unsupported shaft can sag posteriorly in a supine patient. Meanwhile, the proximal fragment may remain flexed through the iliopsoas attachment. The appearance and magnitude of this deformity depend on which part of the lesser trochanter remains attached to the head-neck fragment. A displaced greater trochanter carries the pull of the abductors; lateral wall displacement must be interpreted according to its actual fracture attachments. [18]

These observations should not be turned into a universal rule that gravity always defeats the surgeon in the supine position. A support under the thigh, correction of rotation, an appropriate reduction instrument or limited open reduction may counteract the deformity. Likewise, gluteus maximus should not be depicted as inserting into the greater trochanter: its influence is through the iliotibial tract and the gluteal tuberosity. The anatomical illustration in Chapter 1 shows the relevant attachments; each must be related to its retained fracture fragment.

When a lateral exposure is needed, the tissue layer usually being opened is the fascia lata/iliotibial band, followed where necessary by an appropriate approach around or through vastus lateralis. It is more precise to describe this than to call every fascial incision an incision through the tensor fasciae latae muscle. My practical concern is that traction and limb position can make this layer tense, restrict the working angle and make application of clamps or a Hey Groves clamp awkward. [18]

Lateral positioning without sustained traction



Figure 4.1. Photo-based illustration of the author's lateral setup: the operative hip is uppermost and the limb is supported. An opaque blue modesty drape and a very light illustrated finish have been added. This is an adapted teaching image.

Lateral positioning changes the relationship between gravity, the limb and the surgeon. The affected side lies uppermost. In selected low-energy fractures, supporting and manipulating the limb allows the surgeon to bring the shaft to the proximal fragment and to work directly over the lateral femur. The advantage is freedom to alter the reduction as its three-dimensional behaviour becomes apparent.

“Without traction” in this book means without continuous mechanical traction from a fracture table. It does not prohibit a brief, gentle manual traction manoeuvre when necessary to recover length. Published lateral techniques may include manual traction; therefore, their results should not be described as proof that no traction is ever needed. [21]

Freedom of movement creates a corresponding responsibility. The proximal fragment, trochanteric region and shaft may move independently. Length, rotation and coronal/sagittal alignment must be maintained during guidewire passage, proximal opening, reaming, nail insertion and placement of the cephalic element. An initially good image is not enough if reduction is lost while the implant passes the fracture.

In my preferred approach, the team agrees who supports the limb, who controls the proximal fragment and when fluoroscopy will be repeated. A percutaneous instrument or a limited

exposure is used when required to maintain a reduction that cannot be held by limb positioning alone. The aim is controlled fixation, not the avoidance of an incision at any cost. [18]

The principal technical vulnerability is imaging. A true lateral or appropriate axial image of the head-neck segment can be difficult, especially when the targeting jig overlaps the field. The fluoroscopic path must be rehearsed before preparation and draping. For a long nail, access to the distal femur and locking views must also be confirmed. AO preparation guidance explicitly recommends proving that satisfactory images can be obtained before draping. [22]

What comparative evidence supports

Doğan, Ertürk and Gülabi conducted a prospective randomised comparison involving 80 patients older than 60 years with unstable intertrochanteric fractures. The study compared lateral proximal femoral nailing without a traction table with supine nailing on a traction table and concluded that the lateral method was a viable alternative. This supports the feasibility of a trained lateral technique; it does not establish that lateral positioning eliminates mechanical failure. [23]

Abulsoud and colleagues prospectively studied 96 patients treated with short proximal femoral nails. Lateral positioning was associated with shorter setup and operating times and less blood loss. Reduction measures and Harris Hip Scores did not differ significantly; the reported scores were 67.65 ± 17.06 versus 67.15 ± 17.05. Allocation was by operating day, and the study excluded patients requiring long nails or additional cables/cerclage. Its applicability to the most complex subtrochanteric injuries is therefore limited. [21]

A 2026 retrospective study by Kahraman and colleagues included 68 patients described as having subtrochanteric fractures, treated with long nails: 31 lateral and 37 supine. Reported mean operating-room time was 80.3 versus 108.2 minutes, and fluoroscopy time 151.2 versus 178.2 seconds, favouring lateral positioning. Major mechanical complications or revision occurred in 2/31 and 4/37, respectively; the study did not establish a significant complication advantage. Selection, differing reduction aids and exclusion of three early deaths from the traction-table group limit interpretation. Internal inconsistencies in functional-outcome reporting also warrant caution. This is supporting evidence for feasibility and efficiency, not proof of causally reduced failure. [24]

Position, reduction and fixation must be considered separately. A lateral position can facilitate the surgeon's chosen reduction; it does not itself create medial support. A traction table can produce excellent cortical support. The evidence supports selecting an arrangement that enables dependable reduction and imaging in the hands of the operating team.

Practical comparison



Figure 4.2. The same adapted lateral-positioning view, repeated beside the practical comparison. Added opaque blue draping improves modesty; the side-lying setup and supported limb remain visible. This is not a second camera angle.

Question	Supine traction table	Lateral radiolucent table
Maintaining length	Sustained traction is available	Limb support and intermittent manual assistance may be required
Familiarity	Common training and radiographic workflow	Requires a rehearsed alternative workflow
Proximal access	Can be restricted by torso, pelvic rotation or soft tissues	Often convenient in the author's experience
Open reduction	Entirely possible; working angle depends on setup	Convenient lateral access in selected difficult patterns
Main technical concern	Excessive traction, pressure points and residual sagittal deformity	Maintaining length/rotation and obtaining dependable lateral imaging
Final standard	Stable, appropriately aligned fixation	The same standard

This table combines the author's operative preference with the positioning principles and comparative evidence discussed above. It is not a ranking of safety or failure rates. [18, 19, 20, 21, 22, 23]

Supine and lateral positioning

Separate the body position from the fluoroscopic projection

A Supine traction-table arrangement

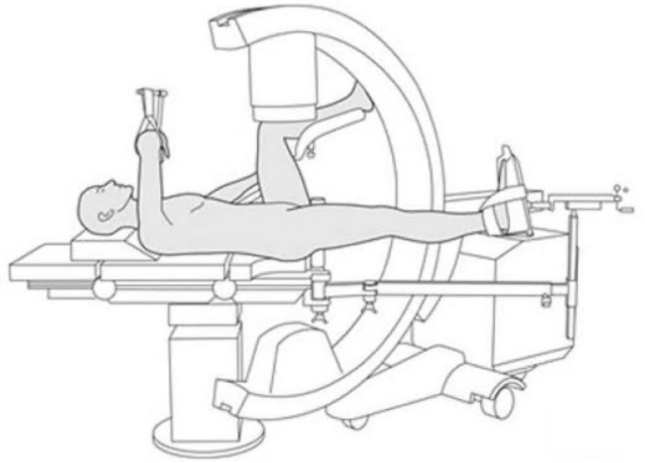

B Lateral positioning with modesty drape



Figure 4.3. A: supplied reference sketch, from a screenshot labelled RCS England, showing a face-up patient on a traction table. B: the photo-based lateral-positioning illustration with an added modesty drape and a light illustrated finish. The operative hip is uppermost. Identifying details are excluded.

Use the actual pelvic orientation

The photo-based illustration keeps the side-lying pelvic orientation and supported uppermost limb visible. Pages 19 and 21 repeat this same view; they do not show separate camera angles. The blue covering is an illustrative addition for modesty.

Feature	Supine traction table	Lateral setup shown
Body orientation	Patient lies face up	Patient lies on the side; operative hip uppermost
Limb control	Table attachments maintain traction and rotation	Team supports and manipulates the limb as needed
Imaging requirement	Rehearse satisfactory orthogonal views	Rehearse satisfactory orthogonal views; lateral positioning does not itself supply a lateral radiograph

The sketch compares positions; the lateral illustration follows the author's photographic setup. In either arrangement, the team must protect pressure points, retain anaesthetic access and confirm imaging before operative draping. [19, 22]

Clinical imaging: the fracture pattern

Original clinical images with identifying overlays removed

A AP pelvis overview

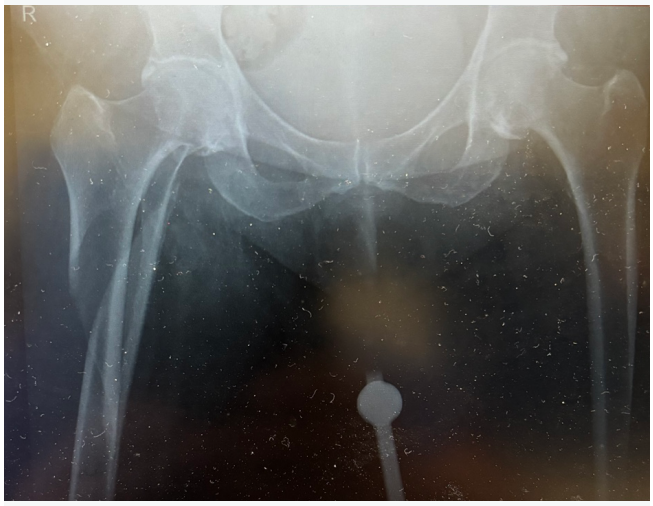

B Proximal femur detail

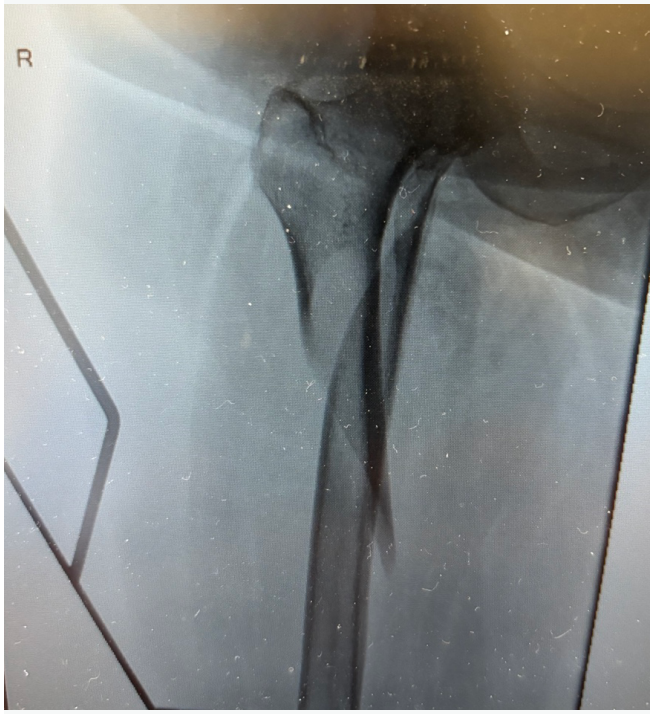

Figure 4.4. Cropped original radiographs. A: AP pelvic overview of the displaced right proximal femoral fracture. B: dedicated proximal-femur projection showing the long oblique extension; it is not labelled as a verified true lateral view. The original right-side marker is retained.

Relate the position to the fracture

The shaft and proximal fragment must be controlled as separate elements. The visible fracture extension helps explain why limb support, rotation and the ability to bring the shaft towards the proximal fragment matter during reduction. The positioning strategy remains subordinate to the achieved reduction.

A pelvic overview does not replace dedicated femoral imaging. Establish the complete fracture extent and obtain suitable orthogonal views. In the lateral setup, confirm access to the hip, fracture and distal femur before draping, particularly when a long nail is planned. [22]

These are photographs of screens: glare, perspective and limited resolution remain. No fracture pixels were generated, retouched or geometrically corrected. The crops support the discussion; they are not calibrated images for measurement.

Fluoroscopy in the lateral setup

Plan the projection before committing to instrumentation

A Entry-guide stage

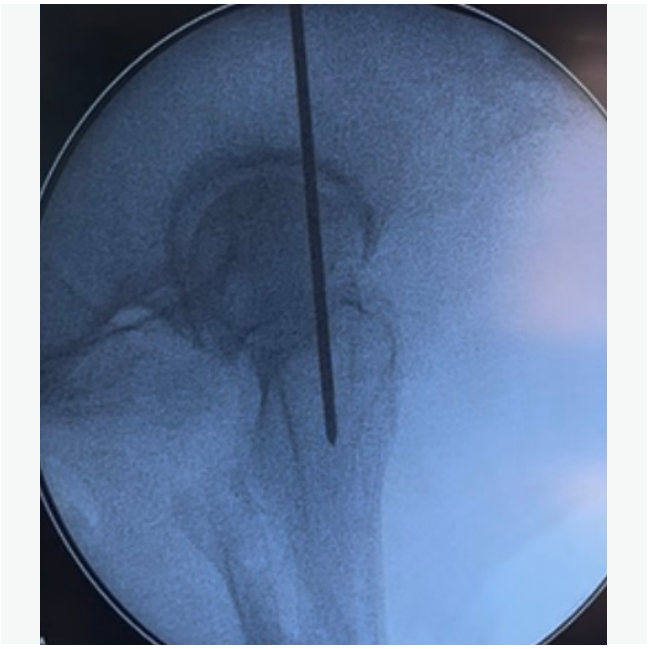

B Proximal opening stage

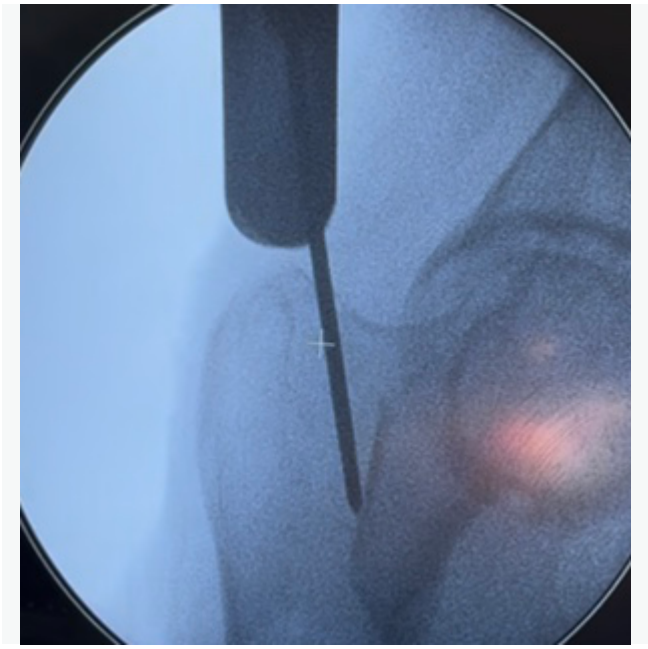

Figure 4.5. Original entry-stage fluoroscopy crops. The guide and proximal opening instrument are shown at different stages; the frames are not asserted to be an orthogonal pair. Completion views are reproduced on pages 29-30. Bone and instrument detail is unchanged.

Read the anatomy, not the number of screens

Two monitors can display the same or a saved projection. A genuine second plane must be established from the anatomy and C-arm orientation. Before draping, rehearse satisfactory images of the entry region, fracture and distal femur; position the display where the team can see it. [22]

Projection	Question to answer
AP / appropriate coronal view	Is the entry consistent with the chosen nail, and are coronal alignment and medial cortical contact satisfactory?
True lateral / appropriate axial view	Are sagittal alignment, anterior contact and guide or implant position satisfactory?
After instrumentation	Has reduction persisted, and can the distal femur and locking region be assessed?

Imaging and clinical checkpoints are developed in Chapter 5. A satisfactory single frame does not establish safe entry, satisfactory final fixation or clinical outcome. [26, 27]

Chapter 5. Reduction and fixation technique

Plan the operation around the fracture

I regard the nail as the means of maintaining a reduction, not as a substitute for understanding it. Before surgery I want to know how the head-neck fragment, trochanteric fragments and shaft relate to one another; which cortex can provide support; and whether the fracture extends beyond the images available. The team should anticipate the manoeuvres and equipment required if the first closed reduction is unsatisfactory.

The plan includes the patient's physiology, pre-injury mobility, bone quality and realistic rehabilitation needs. It also includes the full femoral geometry, canal size, previous implants and the length of any distal extension. Where the apparent injury, mechanism or bone appearance raises concern for a pathological or atypical fracture, that diagnostic pathway must be addressed rather than treating the image as an ordinary fragility injury.

The implant must suit the pattern. NICE recommends an intramedullary nail for subtrochanteric fractures; conventional trochanteric patterns may be suitable for a sliding hip screw, as discussed in Chapter 3. The discussion here concerns fractures for which cephalomedullary fixation has been selected. It is not a recommendation to nail every intertrochanteric fracture. [4]

Reduction before instrumentation

Reduction has four linked objectives: useful cortical contact, appropriate coronal and sagittal alignment, correct rotation, and restored length. The order of the manoeuvres depends on the displacement. In a flexed subtrochanteric proximal fragment, bringing the shaft towards that fragment may be more effective than simply increasing longitudinal traction. Repeat imaging should test whether the apparent correction persists in the other plane. [17]

For the highly unstable fracture, I decide early how the reduction will be held. A gloved hand or supported limb may be sufficient initially, but movement during reaming can undo the result. The assistant, reduction instrument and fluoroscopic sequence must therefore be planned together. I do not accept an attractive AP image if the lateral projection reveals substantial flexion, posterior sag or loss of anterior contact.

Closed methods should be followed by percutaneous assistance or a limited open reduction when necessary. The choice is not a competition for the smallest incision. The useful endpoint is an accurately controlled fracture with a preserved soft-tissue envelope. A limited exposure that enables dependable contact may be preferable to prolonged manipulation followed by residual varus or distraction.

Clamps and selective cerclage

A ball-spiked pusher, a carefully placed Schanz pin, a collinear clamp or a Hey Groves-type clamp may help control a fragment. The instrument must address the actual deformity and remain clear of the guidewire and implant path. Its effect should be reassessed after any change in limb position. Blind placement around the medial femur risks injury to vessels and other soft tissues.

Cerclage can help hold a reducible long spiral or oblique fracture while the nail passes. It is less useful when applied around a comminuted zone that cannot be reconstructed into a meaningful cortical tube. The principle is selective assistance with minimal necessary dissection, not routine circumferential stripping to recover every fragment.

A retrospective study of open versus closed reduction in subtrochanteric fractures found greater operative demands and some complications associated with open reduction, while emphasising that reduction quality remains important. The comparison is confounded by fracture difficulty: the injuries requiring an open approach are often the most complex. Such evidence supports careful selection and tissue handling; it does not justify leaving a poor reduction solely to avoid opening the fracture. [25]

Entry point and preservation of the proximal fragment

The entry point depends on the chosen nail's geometry. Modern trochanteric-entry nails should not be treated as interchangeable with piriformis-entry devices. AO describes aligning the skin incision with the bowed femoral axis and controlling a flexed or abducted proximal fragment before entry. The incision may need to lie farther posteriorly than a superficial view of the greater trochanter suggests. [26]

In my practice, I verify the entry in both projections before accepting it. A fractured greater trochanter is an unreliable landmark if its displacement is ignored. The proximal fragment should remain controlled while the entry is opened, rather than allowing the reamer to push it away from the intended reduction.

AO cautions that a lateral entry or lateral migration of the reamer can drive the construct into varus. A guidewire that appears satisfactory in one image may still be eccentric in the other. Unexpected resistance during passage demands reassessment of alignment, canal size and femoral bow. Forceful advancement should not replace that assessment. [27]

The cephalic element: reduction and position work together

The lag screw or blade should sit in a position that supports secure purchase without penetrating the joint. I favour a caudal position on the AP view when it remains appropriate to the implant and the head-neck anatomy; this should be accompanied by satisfactory central placement in the lateral projection. An excessively peripheral position is not justified simply because it is inferior on AP imaging.

Tip-apex distance (TAD) is the sum of the magnification-corrected distances from the screw tip to the femoral head apex on the AP and lateral radiographs. Baumgaertner and colleagues

studied 198 peritrochanteric fractures treated with a sliding hip-screw device. None of the 120 screws with TAD of 25 mm or less cut out; increasing TAD was associated with cut-out. This was influential evidence for careful positioning, not a guarantee against failure with every contemporary screw or blade. [28]

For a cephalomedullary device, the reduction, head position, depth, bone quality and implant-specific instructions must be considered together. The construct should preserve safe subchondral clearance in both views. Very deep insertion cannot compensate for an unstable fracture, and an acceptable TAD cannot compensate for joint penetration. Numerical positioning targets must be interpreted for the specific device rather than transferred uncritically between designs.

Locking and the final check

After nail passage, repeat the assessment of length, rotation and cortical contact. The locking configuration must match the fracture and the device. For a long nail, examine the distal femur, nail tip and locking screws as well as the hip. The operating team should follow the current manufacturer's technique for the proximal locking mechanism: the details of permitted sliding are device-specific. [27]

Before closure, I want the final images to answer the same questions that shaped the plan. Has useful support been restored? Has the fracture remained reduced during insertion? Is the head element safely placed? Is the distal fixation satisfactory? Is the postoperative loading plan realistic for the construct and the person?

Operative checkpoint	What must be communicated
Reduction	Alignment, cortical contact, residual gaps and any accepted limitation
Implant	Nail and cephalic element position, locking and any supplementary fixation
Soft tissues	Wound condition, relevant neurovascular findings and complications
Recovery	Weight-bearing instruction, walking aids, range of movement and therapy plan
Surveillance	Required radiographs, wound review and reasons for earlier reassessment

For a well-reduced and securely fixed fragility fracture, my intention is to permit early weight bearing as tolerated and unrestricted hip movement, with assistance appropriate to the patient. When fracture biology, fixation or associated injury requires a restriction, I record its reason and the point at which it will be reviewed. A good operation includes a clear handover to the people who will help the patient stand.

Reduction under fluoroscopy

Direct access assists control; imaging tests the result



Control the fragment

A reduction clamp is visible beside the proximal femoral shaft. Choose an instrument that addresses the displacement and leaves the guidewire and nail path accessible.

Confirm both planes

The clamp silhouette cannot establish cortical support. Check medial contact and coronal alignment, then separately assess sagittal alignment and anterior cortical contact.

Recheck after passage

Reduction can change during opening, reaming and nail insertion. Repeat the assessment of length, rotation, alignment and contact as the construct develops. [26, 27]

Figure 5.1. Original fluoroscopy crop showing a reduction-clamp silhouette and the proximal femoral fracture region. The surrounding monitor identity panel, time display, application controls and video strip have been excluded. This is an intraoperative stage, not a final construct or evidence of union.

What these images add to the philosophy

The photo-based positioning illustration shows why I value freedom to support and manipulate the limb. The original imaging returns attention to the endpoint: controlled alignment and useful cortical contact. Neither lateral positioning nor the presence of a clamp proves that this endpoint has been achieved.

Newly supplied completion images are reproduced on pages 29-30. They show the proximal fixation, shaft and distal fixation in the provided projections. No later healing or functional outcome is inferred from the intraoperative images.

Completion imaging: hip and shaft

Final intraoperative views supplied by the author

A Proximal fixation

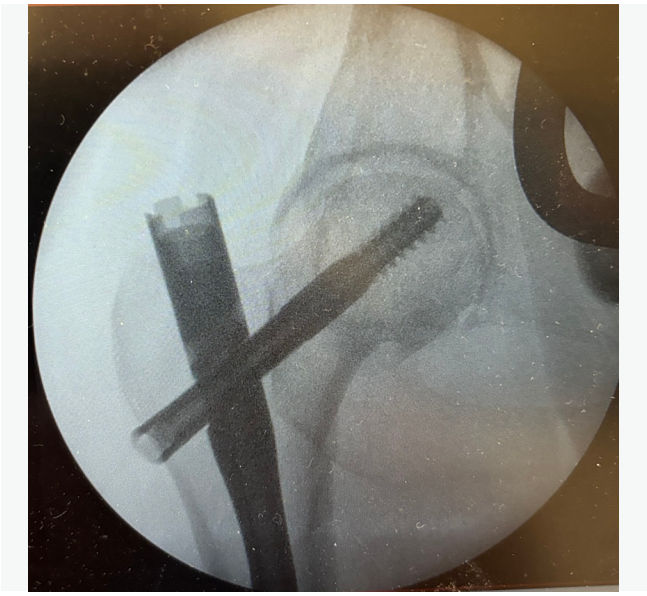

B Additional proximal projection

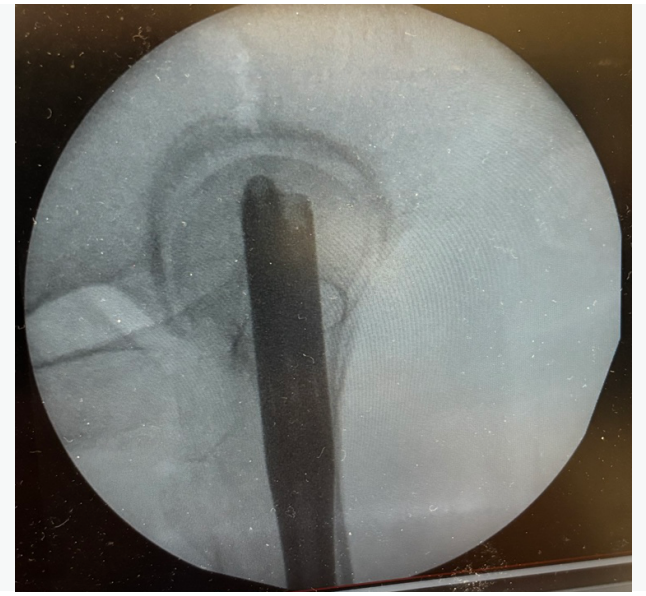

C Shaft and fracture region

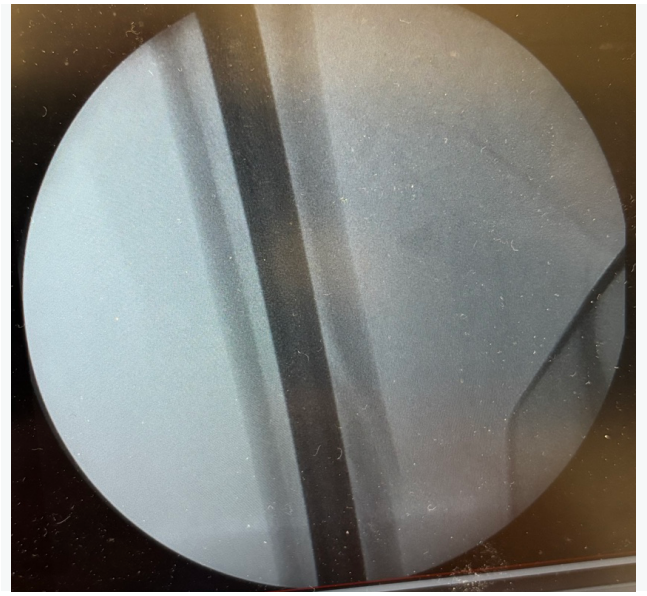

D Additional shaft projection

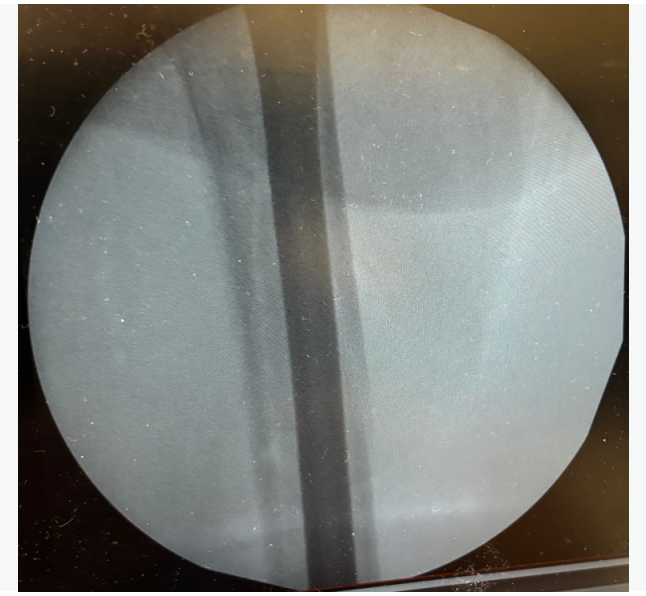

Figure 5.2. Four original image fields from the supplied completion set. A and B show proximal fixation in different projections; C and D show the nail and fracture region along the shaft. These are crops of the source photographs, with no generated or reconstructed bone or implant detail.

Review the proximal fixation and shaft together, then the distal fixation on the following page. The photographs retain screen glare and camera perspective; exact angles, magnification-corrected distances and healing cannot be established from these reproductions. [27, 28]

Completion imaging: distal fixation

The final check extends beyond the proximal femur

A Distal fixation

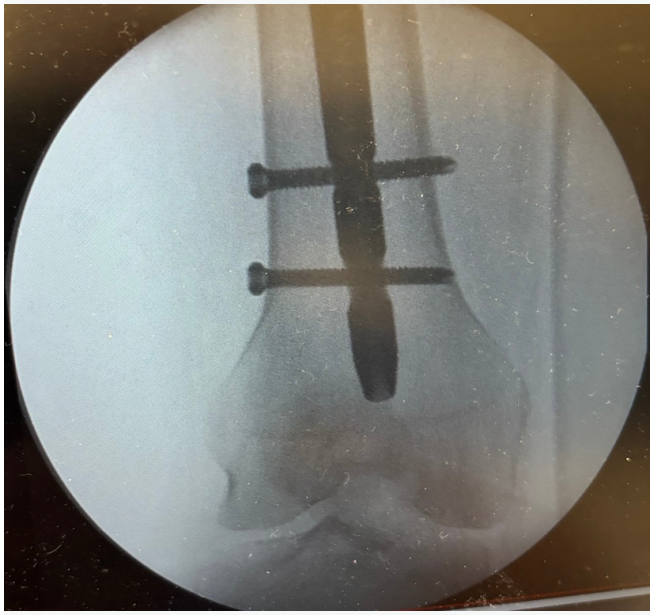

B Alternative distal projection

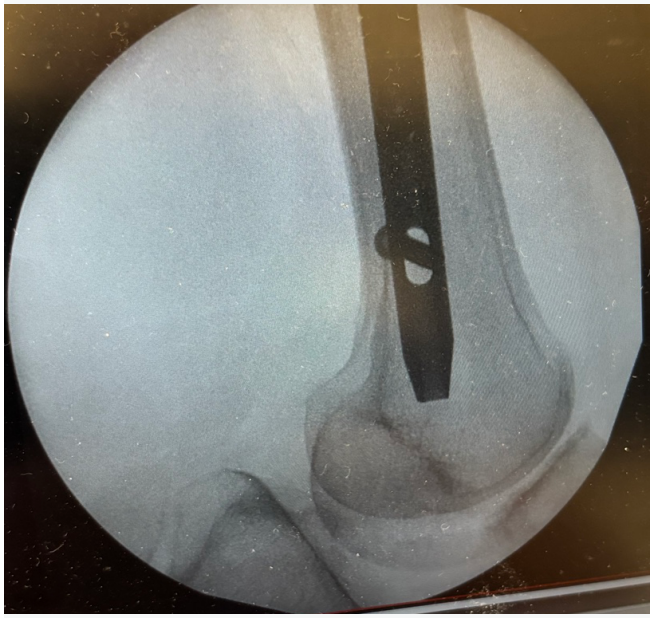

Figure 5.3. Original distal completion views. A shows the nail tip and two transverse locking screws. B provides an alternative view of the distal nail and femoral outline. Identity bands, birth date, record numbers, browser tabs and monitor surrounds have been excluded from the embedded fields.

Document the complete construct

For a long nail, the proximal result and distal fixation belong to the same assessment. Review the nail tip, distal femoral cortex and locking configuration alongside the achieved length, rotation, alignment and cortical contact. The final images should support the operative record and postoperative loading plan. [27]

The newly supplied views now illustrate the completed fixation as well as the earlier reduction and entry stages. They do not show later fracture healing or functional recovery. These remain the subjects of clinical follow-up.

All clinical photographs and fluoroscopy fields in these plates come from the material supplied by the author. Only cropped pixel fields are embedded, with no hidden full-frame image or source EXIF metadata.

Chapter 6. Positive medial calcar support versus anatomical reduction

The clinical objective: bone supporting bone

My reduction philosophy begins with a practical question: when the patient stands, where will the load go? The nail should stabilise the fracture while the major fragments share load wherever possible. If the proximal fragment can collapse into a comminuted region without a cortical stop, the implant must carry a less favourable mechanical burden.

This chapter develops the argument in my earlier manuscript, *Anatomical Reduction versus Positive Medial Calcar/Cortical Support for Unstable Inter- and Sub-trochanteric Femur Fractures*, prepared in November 2025. Its central emphasis is restoration of an anteromedial buttress, avoidance of varus and appropriate implant placement. The manuscript was a case presentation and literature review; it should not be treated as an independently validated comparative clinical study. [18]

“Positive medial calcar support” is useful surgical shorthand. The more precise research term is positive medial cortical support (PMCS), describing the relationship between the medial cortices of the head-neck and shaft fragments. Anteromedial cortical support (AMCS) adds the anterior relationship assessed in the sagittal plane. The terms should not imply that the entire native calcar or posteromedial wall has been reconstructed.

Three reduction relationships

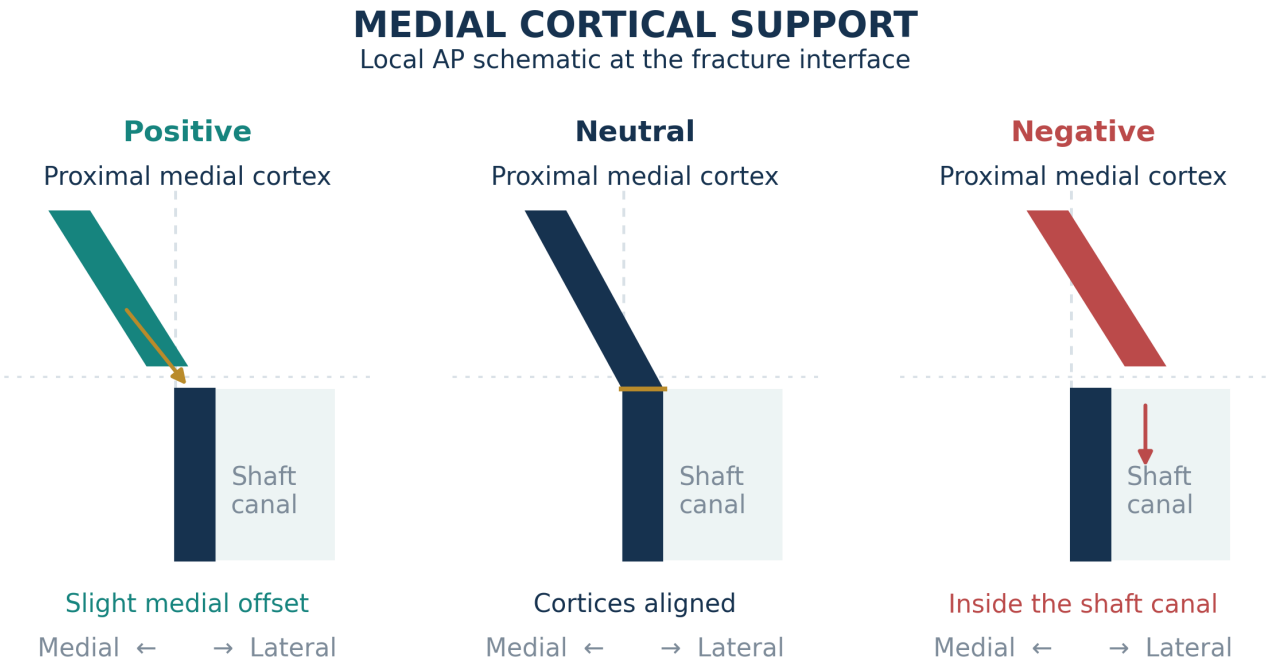

Figure 6.1. Original AP interface schematics: positive, neutral and negative medial cortical support. Only the cortical junction is shown; displacement is exaggerated for teaching. The lateral view must separately establish anterior support. Concept informed by Chang et al. [29].

On an AP image, a neutral relationship means that the medial cortices meet in an approximately anatomical alignment. In positive support, the medial cortex of the proximal head-neck fragment lies slightly medial to that of the shaft, creating a potential cortical buttress after limited impaction. In negative support, that cortex lies lateral to the shaft cortex and may enter the cancellous or medullary region rather than meet a cortical stop. [18, 29]

These are relationships between fragments, not names for a particular neck-shaft angle. Valgus alignment and positive cortical support are distinct observations. A valgus-looking AP image may still hide poor anterior contact, rotation or a residual gap.

Figure 6.1 isolates the cortical interface to distinguish positive, neutral and negative support. It is an AP concept diagram, not a full three-dimensional reconstruction. Intraoperatively, the lateral projection must separately confirm the anterior cortical relationship; satisfactory medial alignment does not excuse posterior displacement or loss of anterior contact.

Why a small positive step may be useful

The proposed benefit is controlled settling. A small amount of sliding can bring the proximal fragment into firmer contact with the shaft, increasing stability. This is a different process from progressive shortening, varus collapse and loss of the head-neck relationship. The intended result is useful contact that arrests unwanted movement.

This concept can be attractive in an unstable pertrochanteric fracture whose posteromedial region is comminuted. Reconstructing every small fragment is not always necessary or desirable, but the relationship between the main head-neck fragment and shaft should be deliberately assessed. An acceptable AP outline, by itself, does not demonstrate a reliable three-dimensional buttress. [18]

Anatomical reduction remains a sound objective when it provides stable cortical contact without excessive stripping or distraction. Positive support is best understood as a controlled alternative in selected fracture patterns, rather than a reason to reject a stable anatomical reduction. Neither should be confused with accepting a large gap or a visibly malaligned construct.

Clinical evidence: encouraging, but not uniform

Chang and colleagues' retrospective series included 127 unstable pertrochanteric fractures: 89 positive, 26 neutral and 12 negative. Mean loss of neck-shaft angle was 0.7°, 4.8° and 8.9°, respectively; mean neck shortening was 2.4, 3.5 and 6.7 mm. These findings favour preservation of support, particularly compared with negative reduction. The groups were not randomised. No patient in any group underwent secondary surgery for implant failure, so this series does not provide a measured reduction in revision risk. All procedures used supine positioning on a fracture table. [29]

In contrast, Mounisamy and colleagues' prospective cohort included 47 patients with AO/OTA 31-A1/A2 fractures: 16 positive, 22 neutral and 9 negative. The investigators did not find significant differences in shortening, neck-shaft angle change, modified Harris Hip Score or time to full weight bearing. The small sample and inclusion of more than one fracture category limit definitive conclusions, but its negative result must be acknowledged. [30]

The reasonable interpretation is that cortical support is clinically relevant, while the superiority of deliberate PMCS over every stable anatomical reduction remains unproven. Patient selection, fracture geometry, bone quality, implant position and the quality of reduction in both planes can obscure or modify an individual radiographic association.

Biomechanics must be read critically

Mao and colleagues compared PMCS with anatomical reduction using finite-element models and mechanical testing. Their PMCS models showed lower displacement and favourable implant and fracture-surface stress behaviour; some anatomical models converted to negative support during loading. This provides a mechanical explanation for why a small positive relationship might preserve contact as the construct settles. It is experimental evidence, not a clinical trial showing fewer revisions. [31]

However, Ling, Qu and Zhou found that anatomical reduction had the highest failure load in their AO/OTA 31-A2.2 synthetic-bone experiment: 984.22 ± 12.63 N, compared with 936.95 ± 16.78 N for PMCS and 918.04 ± 28.86 N for negative support. Anatomical stiffness was not significantly higher than PMCS stiffness, and negative support performed less favourably

overall. It would be incorrect to cite this study as showing universal PMCS superiority over anatomy. Different experimental designs test different aspects of stability. [32]

Together, these studies support avoidance of negative support more consistently than they prove that positive support is always better than anatomy.

Valgus, gap and implant loading

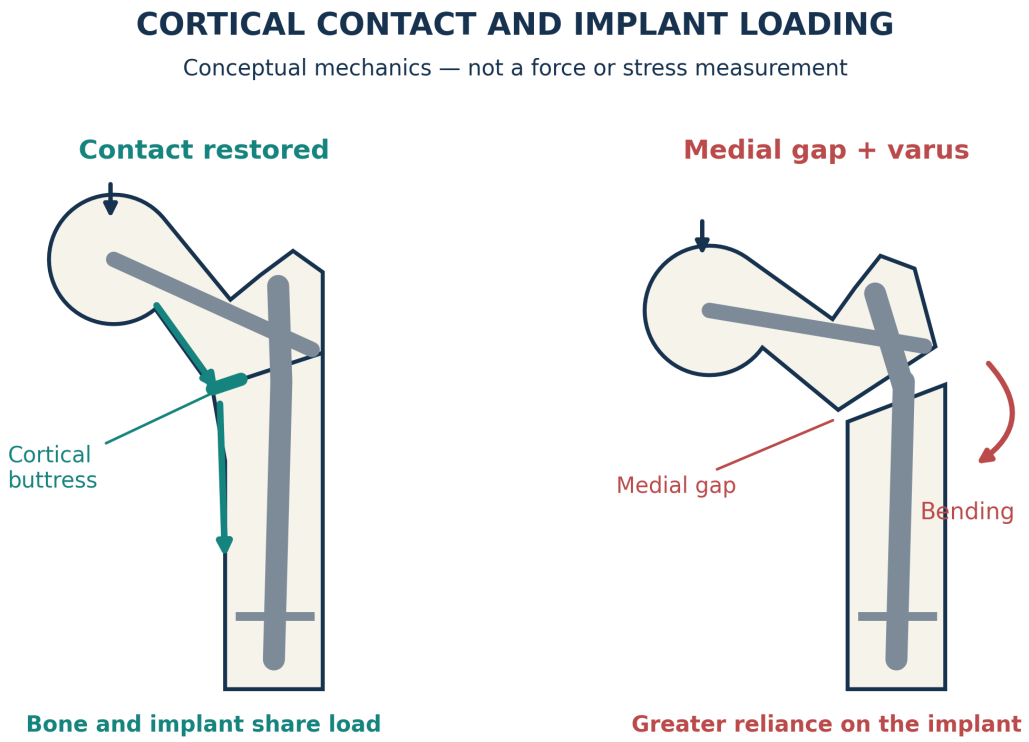

Figure 6.2. Original conceptual load-sharing schematic. Cortical support can help transmit load while the implant stabilises the fracture; a gap and varus increase dependence on the implant. Arrows are qualitative, not calculated forces. No particular valgus angle or failure probability is implied. [31, 32, 34]

In my practice, I seek to avoid varus and accept a modest valgus relationship when it accompanies satisfactory cortical support. This is an operative preference, not a prescription to create excessive valgus. [18]

The assumption that excessive valgus will reliably settle into normal anatomy should not guide fixation. Settling is variable. Excessive translation or distraction can reduce useful contact; alignment may remain altered, and collapse may proceed in an undesirable direction. The target is a stable, appropriate reconstruction at the end of surgery rather than an expectation that postoperative loading will repair malreduction.

Song and colleagues investigated loss of anteromedial support after nailing and found that larger calcar gaps on AP and lateral fluoroscopy were associated with subsequent support failure. Their reported threshold estimates were 4.2 mm and 3.8 mm, respectively. These study-derived thresholds are not universal intraoperative permission limits: they reinforce the need to inspect contact and residual gap in both planes. [33]

A supported reduction may plausibly reduce demand on parts of the implant, as experimental models suggest. The statement that a particular valgus angle prevents nail breakage is stronger than the available clinical evidence. Implant fatigue, nonunion and loading interact, and a technically satisfactory reduction cannot remove every biological or mechanical risk.

The subtrochanteric distinction

Subtrochanteric fractures should not simply inherit every conclusion from pertrochanteric studies. The main fracture lies in a different cortical region; accurate restoration of alignment, length, rotation and medial continuity is particularly important. An intentional step intended to create support at the intertrochanteric region is not a licence to leave a displaced subtrochanteric shaft fracture.

Krappinger and colleagues studied 74 subtrochanteric fractures after intramedullary nailing. Nonunion occurred in 17 patients (23.0%). Varus malalignment, lack of medial cortical support and early autodynamisation were associated with nonunion. The 23% rate belongs to this selected single-centre cohort and is not a general prediction for every subtrochanteric fracture. The study supports correcting varus and restoring support, but does not establish that lateral positioning or deliberate positive translation is superior. [34]

Operative endpoint and follow-up

Before completion, I want to see a coherent construct: acceptable alignment, maintained length and rotation, useful medial and anterior cortical contact where reconstructible, no significant distraction, and an implant positioned according to its design. The cephalic element and the reduction are complementary decisions. A favourable screw position does not correct an unsupported fracture, and cortical support does not excuse a poorly placed screw. [18]

The postoperative record should state the achieved reduction and the intended mobilisation plan. Follow-up should compare serial images for change in alignment, shortening, sliding, union and symptoms. A small amount of controlled impaction may be compatible with healing; progressive pain, progressive varus, unexpected migration or breakage requires assessment.

My preferred combination remains lateral positioning when it improves access, avoidance of varus, and positive or anatomical anteromedial support with dependable fixation. It is a reasoned surgical philosophy supported in parts by clinical and biomechanical literature. Its success must be judged by documented healing, function and complications, rather than by position alone.

Chapter 7. Follow-up: healing the person as well as the fracture

The purpose of follow-up

The operation creates the conditions for recovery. Recovery itself depends on the interaction between mechanical stability, biological healing, rehabilitation and the patient's physiological reserve. A satisfactory postoperative radiograph cannot compensate for dehydration, delirium, inadequate nutrition, untreated pain or an unsafe discharge. Equally, excellent medical care cannot make an unstable fixation construct reliable. In my practice, the surgical and orthogeriatric plans must therefore be discussed together, with a clear explanation of what the patient is permitted and expected to do.

NICE recommends a coordinated Hip Fracture Programme beginning at admission, with orthogeriatric assessment, early rehabilitation goals and continuing links to community, falls and bone-health services. Mobilisation should normally begin on the day after surgery unless a medical or surgical contraindication exists. The operative objective is a construct that permits immediate unrestricted weight bearing. These are goals for the pathway, not a declaration that every individual fixation is safe under every loading condition. [4]

Frailty, cognition and physiological optimisation

Frailty assessment helps explain why two people of the same age may have very different recovery trajectories. Record pre-injury walking ability, independence, cognition, residence, assistance with daily activities and the patient's own priorities. Use the service's validated frailty instrument, interpreted alongside a comprehensive geriatric assessment; a score must not replace individual clinical judgement. Distinguish longstanding cognitive impairment from new delirium, and seek family or carer accounts when the history is uncertain. The aim is to identify reversible barriers and realistic goals, rather than to label a person as incapable of rehabilitation.

Medical review should include volume status, renal function and electrolytes; haemoglobin and the cause of anaemia; diabetes control; cardiopulmonary disease; medication burden; pain; bowel and bladder function; and clinical evidence of infection. Liver disease, anticoagulation and other comorbidities require targeted review when present. Optimisation means correcting relevant abnormalities and adapting treatment to organ function, rather than promising normalisation of every laboratory result. Adequate analgesia should make transfers and therapy possible without causing avoidable sedation.

Comprehensive care can influence function. In a randomised trial of 397 home-dwelling adults aged at least 70 years with hip fracture, Prestmo and colleagues found better mobility at four months with comprehensive geriatric care than with standard orthopaedic care: mean Short Physical Performance Battery scores were 5.12 and 4.38, a difference of 0.74 points (95% CI

0.18-1.30). This was a selected hip-fracture population; its results should not be presented as a guarantee for every frail patient or as evidence for one fixation position. [35]

Nutrition is part of fracture treatment

Screen for malnutrition at admission and repeat assessment during admission. Weight loss, poor intake, swallowing difficulty, dentition, dependence for feeding and cognitive impairment deserve attention even when body mass index appears reassuring. A registered dietitian should assess patients at risk and prescribe an achievable plan, involving nursing staff and family where appropriate. Record what the patient actually eats and drinks. Simply prescribing supplements does not establish that nutritional needs have been met.

Protein and energy provision, hydration and correction of identified deficiencies must be individualised, particularly in renal or hepatic disease. Oral nutrition support is preferred when safe and feasible; swallowing or gastrointestinal problems may require specialist assessment and another route. Severe malnutrition or prolonged negligible intake creates a risk of refeeding complications, requiring a cautious, monitored plan. Serum albumin may reflect inflammation and illness as well as nutrition and should not become the sole assessment of nutritional recovery. [36]

Mobilisation, loading and range of movement

The postoperative instruction must specify loading status, walking aids, movement restrictions, their reason and a review date. For an older adult with satisfactory reduction and secure cephalomedullary fixation, weight bearing as tolerated with assistance is commonly appropriate. It permits loading according to pain and ability; it does not require an exhausted patient to walk independently or bear maximum weight immediately. Hip and knee movement can usually start within comfort, with progressive strengthening and transfer practice.

Restrictions may be justified by a tenuous construct, an uncorrected gap or instability, an associated fracture, intraoperative complication, major soft-tissue repair or a particular revision reconstruction. A young adult with a high-energy injury also requires an individual plan. The AAOS guideline supports considering immediate full weight bearing to tolerance after hip-fracture surgery, while acknowledging limited evidence for this option. Restrictions should therefore be explicit and reviewed rather than continued by default. [37]

Shared responsibility and discharge

The consultant surgeon explains construct stability and mechanical concerns. The orthogeriatrician coordinates medical problems and frailty. Junior doctors carry out and communicate the daily plan under appropriate supervision. Nursing staff identify changes in pain, delirium, intake, skin condition and function. Physiotherapists progress transfers, gait and strength; occupational therapists assess daily activities, equipment and the home environment. Dietitians, pharmacists, social-care professionals and other appropriately supervised team members contribute according to need and competence. The patient and carers should know who holds responsibility for each outstanding problem.

Before discharge, agree the destination, equipment, medication plan, wound care, rehabilitation access, support for meals and personal care, and arrangements for urgent advice. A care package should be functioning when required, not merely requested. The discharge summary must communicate loading instructions and the reason for any restriction. In my view, this communication is as important as recording the implant size: it turns an operation into a usable recovery plan.

Assess thrombosis and bleeding risk. NICE recommends a month of prophylaxis after fragility fractures of the pelvis, hip or proximal femur when thrombosis risk exceeds bleeding risk; agent, timing and dose require individual assessment, including renal function. [38] Falls assessment and secondary fracture prevention should have a named owner. In the HORIZON recurrent-fracture trial, zoledronic acid given within 90 days after hip-fracture repair reduced new clinical fractures from 13.9% to 8.6% over a median 1.9 years. This supports active osteoporosis treatment, selected after appropriate renal, calcium, vitamin-D and other safety assessment, rather than allowing the fracture episode to end without a prevention plan. [39]

Follow-up as an active process

An illustrative schedule is an early wound and functional review at about 10-14 days, radiographs at approximately 3-6 weeks, and repeat assessment about six weeks later to establish progressive union. Further review at six months or one year is selected according to fracture complexity, symptoms and concerns about the joint. AO describes this framework; local pathways may deliver some reviews through community or virtual services. Subtrochanteric nonunion risk and complex reconstruction may justify closer surveillance. [20]

At each review ask whether pain, walking distance and independence are improving. Compare sequential AP and lateral images for alignment, callus, fracture-gap persistence, implant position and migration. Establish whether the apparent radiographic change represents expected controlled impaction or progressive failure. New severe pain, sudden inability to bear weight, shortening, deformity, wound drainage, fever or rapidly deteriorating function warrants earlier assessment. Neither a routine appointment date nor the expectation of postoperative pain should delay investigation of a concerning change.

Chapter 8. Failure: recognise the mechanism before selecting the treatment

Failure is a process, not simply a broken implant

Failure can involve bone, implant, joint, soft tissue, infection or the patient's function. A nail may remain intact despite painful nonunion, and fracture union may coexist with symptomatic shortening or prominent metalwork. The clinical question is therefore broader than whether the metal has broken. Establish what has failed, why it has failed, whether the fracture is united and whether the femoral head and acetabulum remain reconstructable.

Review the original injury, reduction, implant choice, cephalic fixation position, locking, subsequent loading and serial radiographs. Assess infection and host factors without assuming that an apparently mechanical problem is aseptic. Whole-femur AP and lateral radiographs help identify the entire implant and a distal peri-implant fracture; targeted CT can clarify bridging, deformity or bone loss when plain films leave a decision unresolved. Investigations should answer a defined question and contribute to a revision plan.

Principal patterns

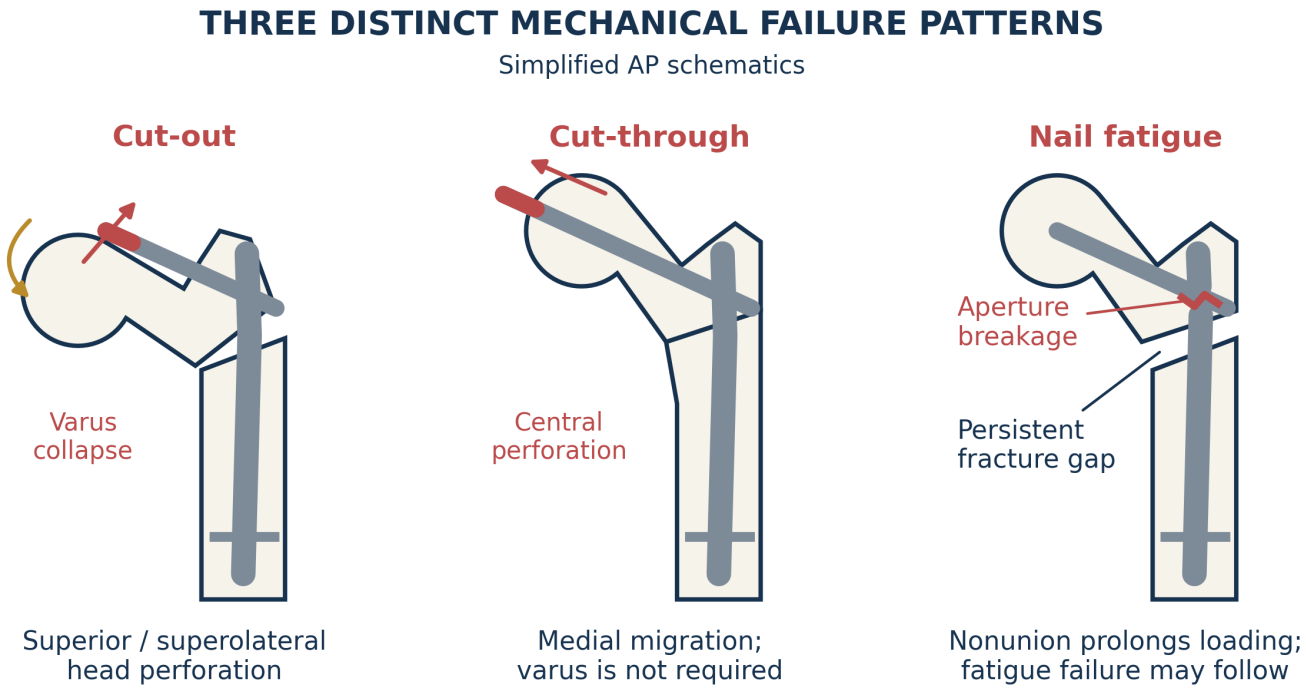

Figure 8.1. Original simplified AP schematics distinguishing varus-associated cut-out, central cut-through and fatigue breakage in an ununited construct. These are illustrative patterns, not patient images; their shapes and displacements are not to scale.

Pattern	What it means	Consequence for assessment
Varus collapse and excessive shortening	Loss of alignment or support with progressive deformation	Assess reduction, medial contact, lateral-wall integrity and union
Cephalic screw or blade cut-out	Superior escape from the head, commonly with varus collapse	Determine head damage and whether the acetabulum is injured
Cut-through or medial migration	More central penetration through the head, which may occur without classic varus cut-out	Check joint penetration, implant mechanism and pelvic structures
Nail or locking-screw breakage	Loss of implant integrity; fatigue may reveal persistent nonunion	Find the unhealed level and underlying instability or biological deficit
Delayed union or nonunion	Healing is not progressing adequately for the clinical context	Distinguish mechanical instability, infection and impaired biology
Osteonecrosis or joint degeneration	Femoral-head collapse or progressive articular disease	Reassess joint preservation versus arthroplasty
Prominent or irritating metalwork	Local soft-tissue conflict, sometimes after fracture impaction	Confirm union and exclude joint, infection and referred-pain causes
Peri-implant fracture	New fracture around or beyond the fixation device	Assess the whole femur and plan fixation or reconstruction as a new problem

The distinction between cut-out and central cut-through is useful because the direction and mechanism of failure differ. Both can damage cartilage and remove the possibility of simple screw exchange. Intrapelvic migration deserves particular caution: before extraction, define proximity to vessels and viscera and obtain appropriate specialist input. A seemingly straightforward removal can become a vascular procedure if an implant has entered the pelvis.

Nonunion and fatigue failure

Subtrochanteric fractures demand particular attention to alignment and cortical load sharing. In a 74-patient cohort, Krappinger and colleagues identified postoperative varus, absent medial cortical support and early autodynamisation as significant nonunion-associated factors. Nonunion was observed in 17 patients (23%). Rates rose with the number of these factors, although the small subgroups make individual prediction uncertain. This cohort supports correction of avoidable mechanical deficiencies; it does not establish a universal nonunion rate. [34]

A broken locking bolt can be an early warning of construct instability. Planned dynamisation is a deliberate intervention, distinct from spontaneous breakage. Revision must address the unhealed fracture's mechanical and biological problems rather than merely exchange the failed metal. [34]

Osteonecrosis and persistent pain after union

Femoral-head osteonecrosis is less characteristic of extracapsular than displaced intracapsular fractures, but it remains an important explanation for later groin pain and collapse. In a retrospective AO/OTA 31-A3 nailing cohort of 193 patients, two patients (approximately 1%) developed avascular necrosis and underwent total hip arthroplasty. This is a study-specific observation, not a rate applicable to all fracture patterns. [40]

Pain after apparent union should be localised. Lateral tenderness may reflect prominence or tendon irritation, whereas groin pain may point to articular pathology; spinal or other referred pain also remains possible. Imaging and examination must establish causation before elective implant removal. Removing fixation from an osteoporotic proximal femur can create a new fracture risk. The absence of a visible break in the nail does not prove that removal is the appropriate solution.

Infection changes the pathway

Persistent drainage, a sinus, wound breakdown, unexpected pain or unexplained nonunion should trigger assessment for fracture-related infection. A normal inflammatory marker does not independently exclude infection. When revision is undertaken, representative deep samples and histology should be considered within an infection protocol. The international fracture-related infection consensus emphasises debridement, stable fixation, management of dead space and adequate soft-tissue coverage, with pathogen-directed treatment. In a clinically stable patient, obtaining appropriate samples before empirical antibiotics improves diagnostic yield; sepsis requires urgent treatment rather than delay for an elective sampling sequence. [41]

Failure management should involve the relevant trauma, reconstruction, infection and medical teams early. The revision operation is an opportunity to correct the reason for failure. It is also a point at which the patient's goals may need to be reconsidered: durable walking, safe transfers, pain relief and control of infection may carry different priorities in different people.

Chapter 9. Outcomes and reconstruction after failure

What counts as success?

Union without implant failure is essential, but it is not the whole outcome. Record pain, walking ability, aids, return to the previous residence, daily independence, reoperation and survival. Compare function with the patient's own baseline. A person who previously walked independently and now requires permanent assistance has experienced a meaningful loss even if the radiograph is satisfactory. Equally, comfortable transfers may represent an important achievement for someone with severe pre-existing disability.

My preferred strategy for selected highly unstable fractures is lateral positioning without sustained table traction, direct control of reduction where necessary, avoidance of varus, and deliberate restoration of cortical support. These priorities express a surgical philosophy. They should be evaluated against recorded outcomes and not be presented as proof that alternative positions are inferior. The useful endpoint is the stable reduction achieved, rather than the position alone.

What the outcome literature supports

Current evidence supports careful reduction and a construct capable of rehabilitation. It does not justify assigning a single low failure rate to the combined package of lateral positioning, positive medial support and valgus. Studies differ in pattern, patient selection, implant, definition of failure and follow-up. A satisfactory anatomical reduction can succeed; a small positive cortical relationship may be useful in the appropriate pertrochanteric pattern. Neither should be confused with deliberate major displacement or excessive valgus. Subtrochanteric reconstruction requires its own attention to length, rotation, alignment and cortical apposition.

Primary study	Population and result	Appropriate interpretation
Jia et al., 2021 [42]	806 propensity-matched older patients with intertrochanteric fractures. Twelve-month implant failure: 39/389 (10.0%) with immediate weight bearing as tolerated versus 35/385 (9.1%) with restriction; risk ratio 1.11, 95% CI 0.69-1.80	No statistically significant increase detected; observational design and confidence interval preclude proof of equivalence. “Immediate” meant starting within seven days, usually with aids
Multicentre subtrochanteric study, 2024 [43]	182 older patients; five implant failures requiring reoperation (2.7%), comprising four cut-outs and one broken nail	Supports considering early full loading after good reduction; does not establish safety for a poorly reduced construct

Primary study	Population and result	Appropriate interpretation
Krappinger et al., 2019 [34]	17/74 subtrochanteric fractures developed nonunion; varus, absent medial cortical support and early autodynamisation were associated factors	Mechanical assessment remains crucial; this selected cohort's rate is not a universal benchmark
AO/OTA 31-A3 nailing cohort, 2019 [40]	Nine of 193 patients (4.7%) underwent reoperation for hardware or fixation failure, with a further two conversions for osteonecrosis	Distinguish mechanical revision from other causes of failure and report the fracture population clearly

Early mobilisation follows satisfactory fixation; it cannot be relied upon to correct malreduction. Follow-up must distinguish controlled impaction from progressive collapse.

Joint-preserving revision

When the head is viable, the joint is preserved and sufficient bone remains, joint-preserving reconstruction is often attractive, particularly in a younger or physiologically robust patient. Correct deformity, restore stability and address the biological deficit. Options include exchange cephalomedullary nailing, augmentation plating, or a fixed-angle plate with compression and selected bone grafting. A structural graft may be useful where a cortical defect requires support; cancellous graft supplies biological material but does not replace stable fixation.

In a retrospective series of 190 aseptic trochanteric/subtrochanteric nonunions, healing at one year was reported in 129/136 (95%) after revision nailing without an auxiliary plate and 51/54 (94%) with a plate. The groups were not randomised, so this does not demonstrate that the plate has no value in an individual unstable reconstruction. [44]

A blade plate remains a specialist option for selected nonunions and deformity correction. A published 68-patient comparison evaluated 95-degree blade plates and revision cephalomedullary nails. Its findings support both as reconstructive tools but are affected by treatment selection and follow-up loss. The plate's stated angle is the implant's fixed geometry; it is not the target femoral neck-shaft angle. A universal prescription of a “90-degree plate with excessive valgus” is therefore inappropriate. Plan the correction against the contralateral anatomy, residual deformity, available bone and the intended mechanical environment. [45]

Conversion arthroplasty

Total hip replacement is often preferable when fixation failure has destroyed the femoral head, penetrated the acetabulum, produced symptomatic joint degeneration, or left insufficient proximal bone for reliable head-preserving reconstruction. Arthroplasty may also suit an older person unlikely to tolerate another prolonged period awaiting union. Hemiarthroplasty remains an option in selected lower-demand patients with preserved acetabular cartilage; the choice depends on joint damage, functional expectations and the reconstructive circumstances.

Conversion is more demanding than routine primary replacement because of retained or broken hardware, deformity, screw holes, bone loss and abductor problems. Stem selection, management of stress risers and restoration of length, offset and stability require planning. In Enocson and colleagues' cohort of 88 conversion arthroplasties after failed trochanteric/subtrochanteric fixation, 14 hips (16%) required reoperation during 5-11 years of follow-up; causes included six periprosthetic fractures, five deep infections and three dislocations. These data illustrate the burden of salvage and should not be used to promise an uncomplicated rescue. [46]

Proximal femoral replacement, excision arthroplasty and exceptional amputation

Proximal femoral replacement may be considered when proximal bone loss is so extensive that conventional fixation or a standard revision stem cannot provide reliable reconstruction. It can bypass an unhealable proximal segment, but it introduces substantial concerns about stability, infection, abductor function and subsequent revision. The UK EPRO cohort includes chronic or failed trauma among its indications and supports treating this as complex salvage, with counselling based on the individual indication and host. It is not a routine response to every broken nail. [47]

Girdlestone excision arthroplasty is an option when infection, inadequate reconstructability or the patient's physiological condition makes implantation unsuitable. It may relieve pain or control infection at the cost of shortening, instability and usually major impairment of walking. A trauma-salvage series of 22 patients underlines that it should be discussed as a compromise with functional consequences, not an equivalent substitute for successful reconstruction. [48]

Amputation is exceptionally rare in this setting. It may become relevant when a limb is nonviable, infection cannot be controlled or repeated reconstruction cannot produce a tolerable limb. Such a decision requires specialist multidisciplinary assessment and discussion of rehabilitation and patient priorities. Mechanical fixation failure alone is not a routine indication. [41]

The intended result is a sound reconstruction that permits movement and recovery of independence. Early loading and comfortable joint movement are appropriate when fixation and medical condition allow. I judge the result through both imaging and the patient's experience, supported by coordinated rehabilitation and planned surveillance.

References

Sources checked on 17 October 2026. Numbered references cover the complete nine-chapter book. Clinical cohorts, laboratory studies and the author’s working manuscript are identified separately; none supplies a universal individual failure probability.

[1] Royal College of Physicians. National Hip Fracture Database annual report 2025. Room for improvement: hip fracture care in 2024. HQIP; 2025. Particularly page 3 for counts and demographics.
Open source

[2] Mattisson L, Bojan A, Enocson A. Epidemiology, treatment and mortality of trochanteric and subtrochanteric hip fractures: data from the Swedish fracture register. BMC Musculoskeletal Disorders. 2018;19:369. doi:10.1186/s12891-018-2276-3.
Open source

[3] Sing CW, Lin TC, Bartholomew S, et al. Global epidemiology of hip fractures: secular trends in incidence rate, post-fracture treatment, and all-cause mortality. Journal of Bone and Mineral Research. 2023;38:1064-1075. doi:10.1002/jbmr.4821.
Open source

[4] National Institute for Health and Care Excellence. Hip fracture: management. Clinical guideline CG124. Main update January 2023; minor analgesia wording amendment July 2025. Current recommendations accessed 17 October 2026.
Open source

[5] AO Foundation. AO Surgery Reference. Simple pertrochanteric fractures with posteromedial involvement. Current online definition of 31A1.3 and lateral-wall assessment.
Open source

[6] AO Foundation. AO Surgery Reference. Multifragmentary pertrochanteric fractures with incompetent lateral wall. Current online definition of 31A2.
Open source

[7] AO Foundation. AO Surgery Reference. Intertrochanteric fractures. Current online definition of 31A3 and subgroups 31A3.1, 31A3.2 and 31A3.3.
Open source

[8] Evans EM. The treatment of trochanteric fractures of the femur. Journal of Bone and Joint Surgery British Volume. 1949;31-B:190-203. PMID:18150534.
Open source

[9] Jensen JS. Classification of trochanteric fractures. Acta Orthopaedica Scandinavica. 1980;51:803-810. doi:10.3109/17453678008990877.
Open source

[10] Boyd HB, Griffin LL. Classification and treatment of trochanteric fractures. Archives of Surgery. 1949;58:853-866. doi:10.1001/archsurg.1949.01240030864012.
Open source

[11] Seinsheimer F. Subtrochanteric fractures of the femur. Journal of Bone and Joint Surgery American Volume. 1978;60:300-306. PMID:649632.
Open source

[12] Russell TA, Taylor JC. Subtrochanteric fractures of the femur. In Browner BD, Jupiter JB, Levine AM, Trafton PG, editors. Skeletal Trauma. Volume 2. Saunders; 1992:1490-1492. Historical classification; see also the linked account by Rizkalla and colleagues, Clinical Orthopaedics and Related Research. 2019;477:257-261. doi:10.1097/CORR.0000000000000505.
Open source

[13] Hsu CE, Shih CM, Wang CC, Huang KC. Lateral femoral wall thickness: a reliable predictor of post-operative lateral wall fracture in intertrochanteric fractures. Bone and Joint Journal. 2013;95-B:1134-1138. PMID:23908432.
Open source

[14] Guyver PM, McCarthy MJ, Jain NP, Poulter RJ, McAllen CJ, Keenan J. Is there any purpose in classifying subtrochanteric fractures? The reproducibility of four classification systems. European Journal of Orthopaedic Surgery and Traumatology. 2014;24:513-518. PMID:23412146.
Open source

[15] AO Foundation. AO Surgery Reference. Simple two-part pertrochanteric fractures. Current online definition of 31A1.2.
Open source

[16] Shane E, Burr D, Abrahamsen B, et al. Atypical subtrochanteric and diaphyseal femoral fractures: second report of a task force of the American Society for Bone and Mineral Research. Journal of Bone and Mineral Research. 2014;29:1-23. doi:10.1002/jbmr.1998.
Open source

[17] AO Foundation. AO Surgery Reference. Antegrade nailing for segmental fragmentary proximal third femoral shaft fractures. Reduction of proximal and subtrochanteric deformity.
Open source

[18] Bakhshayesh P. Anatomical Reduction versus Positive Medial Calcar/Cortical Support for Unstable Inter- and Sub-trochanteric Femur Fractures: A Case Presentation and Review of the Literature. Author-provided working manuscript, prepared 11 November 2025. Unpublished source; used for the author’s operative philosophy. Patient-level material is not reproduced.

[19] Apivatthakakul T, Oh JK; Baumgaertner M (executive editor). Supine patient position on a fracture table. AO Surgery Reference. Accessed 17 October 2026.
Open source

[20] AO Foundation. Nailing (short nail) for intertrochanteric fractures. AO Surgery Reference. Accessed 17 October 2026.
Open source

[21] Abulsoud MI, Ibrahim MAA, Mohammed AS, et al. Proximal femoral nailing for unstable trochanteric fractures: lateral decubitus position or traction table? A case-control study of 96 patients. SICOT-J. 2024;10:47. doi:10.1051/sicotj/2024041.
Open source

[22] AO Foundation. Supine with manual traction. AO Surgery Reference. Accessed 17 October 2026.
Open source

[23] Doğan N, Ertürk C, Gülabi D. Is proximal femoral nailing of unstable intertrochanteric fractures in the lateral decubitus position without a traction table as safe and effective as on a traction table? Injury. 2022;53(2):555-560. doi:10.1016/j.injury.2021.11.017.
Open source

[24] Kahraman HÇ, Bilgin E, Gültekin O, Yavuz ÖM, Yavuz O, Yılmaz B. Lateral decubitus positioning was associated with improved efficiency and functional outcome compared with traction table positioning for cephalomedullary nailing of subtrochanteric femur fractures: a retrospective comparative study. BMC Musculoskeletal Disorders. 2026;27:397. doi:10.1186/s12891-026-09843-5.
Open source

[25] Panteli M, Vun JSH, West RM, Howard A, Pountos I, Giannoudis PV. Management of subtrochanteric femur fractures: is open reduction associated with poor outcomes? Eur J Trauma Emerg Surg. 2022;48:1759-1768. doi:10.1007/s00068-021-01834-6.
Open source

[26] AO Foundation. AO Surgery Reference. Approach for proximal femoral nailing. Current online guidance.
Open source

[27] AO Foundation. AO Surgery Reference. Nailing (long nail) for intertrochanteric fractures. Current online guidance.
Open source

[28] Baumgaertner MR, Curtin SL, Lindskog DM, Keggi JM. The value of the tip-apex distance in predicting failure of fixation of peritrochanteric fractures of the hip. J Bone Joint Surg Am. 1995;77:1058-1064. doi:10.2106/00004623-199507000-00012.
Open source

[29] Chang SM, Zhang YQ, Ma Z, Li Q, Dargel J, Eysel P. Fracture reduction with positive medial cortical support: a key element in stability reconstruction for the unstable pertrochanteric hip fractures. Archives of Orthopaedic and Trauma Surgery. 2015;135:811-818. doi:10.1007/s00402-015-2206-x.
Open source

[30] Mounisamy P, Suresh H, Chandrashekar S, D U, Jeyaraman N, Jeyaraman M, Muthu S. Medial cortical reduction does not influence outcomes in geriatric intertrochanteric femur fractures treated with proximal femoral nail. World Journal of Orthopedics. 2025;16(4):106862. doi:10.5312/wjo.v16.i4.106862.
Open source

[31] Mao W, Chang SM, Zhang YQ, Li Y, Du SC, Hu SJ, Yang A, Zhou KH. Positive medial cortical support versus anatomical reduction for trochanteric hip fractures: Finite element analysis and biomechanical testing. Computer Methods and Programs in Biomedicine. 2023;234:107502. doi:10.1016/j.cmpb.2023.107502.
Open source

[32] Ling L, Qu Z, Zhou K. Effect of Fracture Reduction with Different Medial Cortical Support on Stability After Cephalomedullary Nail Fixation of Unstable Pertrochanteric Fractures: A Biomechanical Analysis. Indian Journal of Orthopaedics. 2022;56(1):34-40. doi:10.1007/s43465-021-00443-0.
Open source

[33] Song H, Chang SM, Hu SJ, Du SC, Xiong WF. Calcar fracture gapping: a reliable predictor of anteromedial cortical support failure after cephalomedullary nailing for pertrochanteric femur fractures. BMC Musculoskeletal Disorders. 2022;23:175. doi:10.1186/s12891-021-04873-7.
Open source

[34] Krappinger D, Wolf B, Dammerer D, Thaler M, Schwendinger P, Lindtner RA. Risk factors for nonunion after intramedullary nailing of subtrochanteric femoral fractures. Archives of Orthopaedic and Trauma Surgery. 2019;139:769-777. doi:10.1007/s00402-019-03131-9.
Open source

[35] Prestmo A, Hagen G, Sletvold O, et al. Comprehensive geriatric care for patients with hip fractures: a prospective, randomised, controlled trial. Lancet. 2015;385:1623-1633. doi:10.1016/S0140-6736(14)62409-0.
Open source

[36] National Institute for Health and Care Excellence. Nutrition support for adults: oral nutrition support, enteral tube feeding and parenteral nutrition. Clinical guideline CG32. Updated 2017.
Open source

[37] American Academy of Orthopaedic Surgeons. Management of Hip Fractures in Older Adults: Evidence-Based Clinical Practice Guideline. 3 December 2021.
Open source

[38] National Institute for Health and Care Excellence. Venous thromboembolism in over 16s: reducing the risk of hospital-acquired deep vein thrombosis or pulmonary embolism. Guideline NG89.
Open source

[39] Lyles KW, Colón-Emeric CS, Magaziner JS, et al. Zoledronic acid and clinical fractures and mortality after hip fracture. N Engl J Med. 2007;357:1799-1809. doi:10.1056/NEJMoa074941.
Open source

[40] Hoffmann MF, Khoriaty JD, Sietsema DL, Jones CB. Outcome of intramedullary nailing treatment for intertrochanteric femoral fractures. J Orthop Surg Res. 2019;14:360. doi:10.1186/s13018-019-1431-3.
Open source

[41] Metsemakers WJ, Morgenstern M, Senneville E, et al. General treatment principles for fracture-related infection: recommendations from an international expert group. Arch Orthop Trauma Surg. 2020;140:1013-1027. doi:10.1007/s00402-019-03287-4.
Open source

[42] Jia X, Qiang M, Zhang K, Han Q, Wu Y, Chen Y. Influence of timing of postoperative weight-bearing on implant failure rate among older patients with intertrochanteric hip fractures: a propensity score matching cohort study. Front Med. 2021;8:795595. doi:10.3389/fmed.2021.795595.
Open source

[43] SanJosé-Pardo I, Valle-Cruz JA, Donadeu-Sánchez S, et al. Is immediate weight bearing safe for subtrochanteric femur fractures in elderly patients treated by cephalomedullary nailing? A multicentric study in one hundred eighty-two patients. Eur J Orthop Surg Traumatol. 2024;34:2595-2603. doi:10.1007/s00590-024-03897-8.
Open source

[44] Dietze C, Brand A, Friederichs J, Stuby F, Schneidmueller D, von Rüden C. Results of revision intramedullary nailing with and without auxillary plate in aseptic trochanteric and subtrochanteric nonunion. Eur J Trauma Emerg Surg. 2022;48:1905-1911. Published online 2021. doi:10.1007/s00068-021-01664-6.
Open source

[45] Rehme-Roehrl J, Brand A, Dolt A, et al. Functional and radiological results following revision blade plating and cephalomedullary nailing in aseptic trochanteric and subtrochanteric nonunion. J Clin Med. 2024;13:3591. doi:10.3390/jcm13123591.
Open source

[46] Enocson A, Mattisson L, Ottosson C, Lapidus LJ. Hip arthroplasty after failed fixation of trochanteric and subtrochanteric fractures: a cohort study with 5-11 year follow-up of 88 consecutive patients. Acta Orthop. 2012;83:493-498. doi:10.3109/17453674.2012.688724.
Open source

[47] Wijesekera MP, Pandit HG, Palan J, et al. A UK multicentre cohort study of clinical outcomes of proximal femoral replacement for nononcological conditions: the EndoProsthetic Replacement for nonOncological conditions (EPRO) study. Bone Joint J. 2025;107-B:625-631. doi:10.1302/0301-620X.107B6.BJJ-2024-1304.R1.
Open source

[48] Sharma H, Kakar R. Outcome of Girdlestone's resection arthroplasty following complications of proximal femoral fractures. Acta Orthop Belg. 2006;72:555-559.

Open source

Illustrations, provenance and evidence

The anatomical teaching plate was supplied by the author and credits his original sketch. Epidemiology charts use published aggregate data. The Swedish cohort chart acknowledges Mattisson and colleagues (CC BY 4.0); the UK charts acknowledge the National Hip Fracture Database. Classification, cortical-support, load-sharing and failure diagrams remain simplified teaching schematics.

The cover and Figures 4.1 and 4.2 reuse one AI-assisted adaptation of the lateral-positioning photograph supplied by the author. Opaque blue draping and a very light illustrated finish improve modesty. The side-lying orientation and limb support follow the source. This is an adapted teaching illustration, not an unaltered documentary photograph or a separate operative stage.

Figure 4.3 compares the supplied supine traction-table sketch with the same adapted lateral illustration. The sketch came in a screenshot labelled RCS England; its original publication details were not supplied. It is a comparison image, not a lateral-positioning view or an original drawing by this author.

Figures 4.4, 4.5 and 5.1-5.3 reproduce original radiographic or fluoroscopic fields, including six newly supplied completion views. Names, birth dates, record numbers, institution/date overlays and application controls are excluded. Only cropped raster fields are embedded; hidden full-frame source photographs and EXIF data are not included. Bone and implant pixels were not regenerated, enhanced or warped.

Screen glare, camera perspective and source-image resolution remain. The completion views document the supplied final intraoperative appearance; no later union or functional outcome is inferred. Positioning and imaging captions follow AO Surgery Reference [19, 22, 27]. The wider literature review remains that of 17 October 2026.

First-person passages develop Mr Peyman Bakhshayesh's dictated surgical philosophy. The earlier case-and-review manuscript informed Chapter 6. This is a professional educational book rather than a systematic review or device-specific operative manual. Implant instructions, local policies and individual clinical judgement remain necessary.

Author and edition

Mr Peyman Bakhshayesh, MD, PhD, MBA
Consultant Trauma and Orthopaedic Surgeon
Nine chapters - modesty-adapted positioning illustrations, 19 October 2026
peymanorthopaedics.world